

RESISTANT *HELICOBACTER PYLORI*

***Helicobacter pylori*-induced enlarged-fold gastritis is associated with increased mutagenicity of gastric juice, increased oxidative DNA damage, and an increased risk of gastric carcinoma**

HIROYUKI NISHIBAYASHI,* SHUJI KANAYAMA,* TATSUYA KIYOHARA,* KATSUMI YAMAMOTO,* YOSHIJI MIYAZAKI,* YUICHI YASUNAGA,* YASUHISA SHINOMURA,* TATSUYA TAKESHITA,[†] TORU TAKEUCHI,[‡] KANEHISA MORIMOTO[§] AND YUJI MATSUZAWA*

Departments of *Internal Medicine and Molecular Science and [§]Social and Environmental Medicine, Graduate School of Medicine, Osaka University, Osaka, [†]Department of Public Health, Wakayama Medical University, Wakayama, and [‡]Department of Hygiene, Graduate School of Medical Science, Kagoshima University, Kagoshima, Japan

Abstract

Background and Aim: The severe inflammation, increased cell proliferation and marked acid inhibition observed in subjects with *Helicobacter pylori*-associated enlarged-fold gastritis suggest that enlarged-fold gastritis may be a risk factor for gastric carcinoma. The purpose of the present study was to determine whether a relationship exists between enlarged-fold gastritis and gastric carcinoma.

Methods: One hundred and thirty-five *H. pylori*-positive patients with early gastric carcinoma and 141 age- and sex-matched *H. pylori*-positive controls without gastric carcinoma were involved in the study. The widths of gastric body folds were measured by double-contrast radiographs. The mutagenicity of gastric juice was assayed using the Ames test and *Salmonella typhimurium* TA-98 or TA-100 with S9-mix. Levels of 8-hydroxydeoxyguanosine (8-OHdG) in gastric mucosa were examined using high-performance liquid chromatographic-electrochemical detection.

Results: An upward shift in the distribution of gastric fold widths in *H. pylori*-positive patients with early gastric carcinoma was found. Enlarged-fold gastritis (fold width ≥ 5 mm) was observed in 81% of the patients with gastric carcinoma, compared with 46% of *H. pylori*-positive controls. The odds ratio for gastric carcinoma increased with increasing fold width to a maximum of 35.5 in persons with fold width ≥ 7 mm. The prevalence of diffuse-type early gastric carcinoma in the body region increased with increasing fold width. The mutagenicity of gastric juice from the patients with enlarged-fold gastritis was significantly higher than that in *H. pylori*-negative controls and *H. pylori*-positive patients without enlarged folds. Mucosal 8-OHdG levels in the body region of patients with enlarged-fold gastritis were significantly higher than in *H. pylori*-negative controls and *H. pylori*-positive patients without enlarged-fold gastritis. Eradication of *H. pylori* significantly decreased the mutagenicity of gastric juice and 8-OHdG levels in the gastric mucosa from patients with enlarged-fold gastritis.

Conclusion: A significant association is suggested between enlarged-fold gastritis and gastric carcinoma.

© 2003 Blackwell Publishing Asia Pty Ltd

Key words: 8-hydroxydeoxyguanosine, enlarged-fold gastritis, *Helicobacter pylori*, mutagenicity, oxidative DNA damage.

INTRODUCTION

Gastric body folds are generally considered to be enlarged when the widest fold is ≥ 5 mm, based on the Sydney system, as well as on previous studies.¹⁻⁵ Enlarged folds in the gastric body are often observed during radiographic or endoscopic examination of adults. Enlarged gastric folds are associated with a variety of diseases, including hypertrophic gastritis, Ménétrier's diseases, Zollinger-Ellison syndrome, primary gastrin cell hyperplasia, carcinoma, and lymphoma.^{6,7} It has recently been suggested that *Helicobacter pylori*-induced gastritis may be a possible cause of enlarged gastric folds.^{8,9} The authors have previously reported that the eradication of *H. pylori* improved the inflammation of the gastric mucosa and decreased fold width in *H. pylori*-positive subjects with enlarged folds, that is, enlarged-fold gastritis.⁴ In agreement with the authors' findings, an improvement in gastric-fold thickening after eradication of *H. pylori* has been reported by Stolte *et al.*¹⁰ and Avunduk *et al.*¹¹ Thus, *H. pylori*-associated enlarged-fold gastritis constitutes a subgroup of the population with *H. pylori* infections.

It is now a generally accepted fact that *H. pylori* is an important cause of gastric carcinoma. The International Agency for Research on Cancer classified *H. pylori* as a group 1 carcinogen.¹² A recent prospective study in Japan demonstrated that gastric carcinoma developed in persons infected with *H. pylori*, but not in uninfected persons.¹³ Because the great majority of *H. pylori*-associated gastritis subjects never develop neoplasias, the logical next step would be to identify the factors that precisely determine risk among the *H. pylori*-infected population. A long-recognized critical factor in *H. pylori*-induced gastric carcinogenesis is gastric acid secretion. In subjects with gastritis confined to the antral region, gastric acid secretion is normal or increased. Such subjects have an increased risk of duodenal ulceration, but little association with an increased risk of gastric carcinoma has been found. In contrast, gastritis involving the body region leads to hypochlorhydria and an increased risk of gastric carcinogenesis. In earlier studies,^{4,5,14,15} the authors have reported that enlarged-fold gastritis is accompanied by a massive infiltration of inflammatory cells, and by profound production of interleukin-1 β and hepatocyte growth factor, which decrease gastric acid secretion and increase the rate of proliferation of the gastric epithelial cells. Thus, among an *H. pylori*-infected population, subjects with enlarged-fold gastritis may have a relatively increased risk of gastric carcinogenesis.

In the present study, the prevalence of enlarged gastric fold in patients with gastric carcinoma was examined. In an effort to obtain molecular evidence for an association between enlarged-fold gastritis and gastric carcinogenesis, the authors also examined the mutagenicity of gastric juice and the formation of oxidative DNA damage in gastric mucosa from the subjects with enlarged-fold gastritis.

METHODS

Measurement of width of gastric body fold

One hundred and thirty-five *H. pylori*-positive patients with early gastric carcinoma (125 men, 10 women; age range 29–71 years, mean 54 years) and 141 age- and sex-matched *H. pylori*-positive controls without gastric carcinoma (130 men, 11 women; age range 29–69 years, mean 53 years) were analyzed (Table 1). Early gastric carcinoma was pathologically diagnosed, as defined by the Japanese Gastroenterological Society, by the growth of a malignant tumor confined to the mucosa and submucosa of the stomach regardless of the presence or absence of metastatic disease in the perigastric lymph node. Advanced gastric carcinoma, in which carcinoma cells are deeply infiltrated beyond the submucosal layer, was not included in the present study, to avoid possible thickening of gastric folds as a result of the invasion of carcinoma cells. All patients and controls were members of health insurance organizations in Osaka, and participated in mass screening programs for gastric carcinoma using radiographs.

Between 1990 and 2000, 135 *H. pylori*-positive patients with early gastric carcinoma were enrolled. *Helicobacter pylori* infection was identified by histological examination, a rapid urease test (CLO; Delta West, Bentley, Australia), and a serological evaluation. Patients in whom any of these assays were positive were considered to be *H. pylori*-positive. Two hundred and forty healthy subjects without gastric carcinoma were examined for *H. pylori* infection using HM-CAP anti-*H. pylori* immunoglobulin G EIA (Enteric Products, Westbury, NY, USA), and 141 subjects were positive; these subjects were age- and sex-matched with carcinoma patients. Informed consent for testing *H. pylori* infection was obtained from all subjects. In each person, the widths of the gastric body folds were measured by a computerized image analyzer on double-contrast radiographs of the appropriately distended stomach in the

Table 1 Clinical features of the 135 patients and 141 controls studied

	Patients	Controls
Age in years (range)	54 (29–71)	53 (29–69)
Sex		
Male	125	130
Female	10	11
Tumor site		
Antrum/prepylorus	44	
Body	90	
Fundus	1	
Tumor size in mm (range)	23 (5–85)	
Histological type		
Intestinal	66	
Diffuse	69	
Depth of invasion		
Mucosal	75	
Submucosal	60	

supine position; the carcinoma lesions were masked and the measurer had no knowledge of the disease status of any of the patients. The median value of randomly measured widths in 11 different locations was regarded as the gastric body fold width in each person. To obtain reproducible results, a standardized protocol was employed in all patients by using a fixed amount of effervescent powder and contrast medium: 150 mL of 180% barium sulfate with 5 g of effervescent powder.

Measurement of mutagenicity of gastric juice

Fifteen patients with enlarged-fold gastritis (13 men, two women; age range 30–60 years, mean 45 years), seven *H. pylori*-positive patients without enlarged folds (six men, one woman; age range 30–50 years, mean 43 years) and six *H. pylori*-negative patients with dyspeptic symptoms (four men, two women; age range 39–62 years, mean 46 years) were examined. Informed consent was obtained from all subjects and the investigation was approved by the Research Ethical Committee of Osaka University Medical School. Patients were divided into three groups after double-contrast radiographs and endoscopic examination as described above. The diagnosis of *H. pylori* infection was made based on a positive culture (Department of Chemotherapy, Pharmacological Research Laboratory, Fujisawa Pharmaceutical, Osaka, Japan) and/or by the result of a urease test (CLO; Delta West) using biopsy specimens from the antrum and the greater curvature of the upper portion of the gastric body.^{16,17}

After overnight fasting and discarding the residual gastric juice in the stomach, new gastric juice was collected for 30 min using a sterile gastric tube. The gastric juice (0.1 mL) was assayed for mutagenicity using the Ames test and *Salmonella typhimurium* TA-98 or TA-100 with S9-mix. An equal volume of physiological saline was used as a control. The mutagenicity of the gastric juice was evaluated as the total number of revertant colonies obtained from the total amount of the gastric juices. Twelve patients with enlarged-fold gastritis received triple therapy of clarithromycin, 400 mg twice daily; amoxicillin 1500 mg three times daily; and lansoprazole 30 mg once daily for 2 weeks, and mutagenicity was re-examined in 12 patients 2 months after eradication of *H. pylori*.

Measurement of 8-hydroxydeoxyguanosine levels in the gastric mucosa

8-Hydroxydeoxyguanosine (8-OHdG), which causes DNA mutation *in vivo* and *in vitro*, represents a sensitive marker of oxidative DNA damage. The 8-OHdG levels in gastric mucosa were examined in 13 patients with enlarged-fold gastritis (10 men, three women; age range 23–58 years, mean 45 years), nine *H. pylori*-positive patients without enlarged folds (six men, three women; age range 25–68 years, mean 50 years) and 11 *H. pylori*-negative patients with dyspeptic symptoms (eight men, three women; age range 27–60 years, mean

43 years). Informed consent was obtained from all subjects and the investigation was approved by the Research Ethical Committee of Osaka University Medical School.

Patients were divided into three groups after double-contrast radiographs and endoscopic examination as described above. Four biopsy samples were taken from the antrum and the corpus at endoscopy in all subjects. The samples were immediately frozen in liquid nitrogen and kept at -80°C until the 8-OHdG level was measured. In nine patients with enlarged-fold gastritis, the samples were taken before and 2 months after eradication of *H. pylori*. DNA extraction and digestion were carried out inside an anaerobic incubator EAN-140 (Tabai Espec, Osaka, Japan) to prepare samples under oxygen-free conditions. DNA was extracted from the samples using proteinase K, lysis buffer, and 99.5% ethanol without phenol. The DNA was hydrolyzed to deoxynucleosides by digestion with nuclease P1, followed by alkaline phosphatase. The 8-OHdG levels were detected using high-performance liquid chromatographic-electrochemical detection and expressed as the ratio of 8-OHdG/ 10^5 deoxyguanosine.¹⁸

Histological evaluation of inflammation in the gastric mucosa

In addition to 8-OHdG levels, infiltration of mononuclear and polymorphonuclear cells was also estimated in 19 *H. pylori*-positive subjects. Biopsy specimens were fixed with 10% phosphate-buffered formalin. Thin sections of paraffin-embedded tissues were stained with hematoxylin and eosin for evaluation of mononuclear and polymorphonuclear infiltration. In the biopsy specimens, infiltration of mononuclear and polymorphonuclear cells were graded as follows: 0 = none or minimal, 1 = mild, 2 = moderate, and 3 = severe.² When the score of biopsy specimen was 0 or 1, the degree of polymorphonuclear infiltration and mononuclear infiltration was considered to be mild. When the score was 2 or 3, it was considered to be severe.

Statistical analysis

Statistical analyses were performed using the Mann-Whitney *U*-test and Student's *t*-test. Statistical significance was assigned for any *P*-value <0.05 . Data were shown as mean \pm SEM.

RESULTS

Comparison of gastric body fold width

Distribution of the gastric body fold widths is presented in Figure 1. A significant upward shift of width distribution in *H. pylori*-positive patients with early gastric carcinoma was found ($P < 0.01$). An enlarged gastric fold (fold width ≥ 5 mm) was observed in 81% of the patients with gastric carcinoma, compared with 46% of

H. pylori-positive controls. A fold width in excess of 7 mm was observed in 18% of patients with gastric carcinoma, compared with only 1.4% of *H. pylori*-positive controls. The odds ratio for gastric carcinoma increased with increasing fold width to a maximum of 35.5 in persons with a fold width of ≥ 7 mm (Table 2). In all cases of gastric carcinoma, invasion of carcinoma cells was restricted to within the submucosal layer, and the absence of fold thickening as a result of the massive invasion of carcinoma cells and/or fibrosis was histologically confirmed in the resected specimens. Furthermore, radiographs taken more than 1 year before the diagnosis of carcinoma were available in 97 of 135 cases with early gastric carcinoma, and no significant changes in fold widths were found (5.7 ± 0.1 mm compared with 5.8 ± 0.1 mm, previous and final fold widths, respectively, $P = 0.42$). Thus, an association between enlarged folds and gastric carcinoma is not merely a secondary phenomenon resulting from carcinoma development.

Histology and location of gastric carcinomas

Gastric carcinomas can be divided into two types according to Lauren's classification: intestinal and dif-

fuse types. An association between the gastric-body-fold width and the histology of gastric carcinoma was found (Fig. 2). The prevalence of diffuse-type early gastric carcinoma increased from 31% to 71% of the total cases with increasing fold width. Mean fold widths were significantly different between intestinal- and diffuse-type gastric carcinomas (5.1 ± 0.1 mm compared with 5.9 ± 0.2 mm, respectively, $P < 0.01$). Thus, enlarged-fold gastritis may be a disorder that may precede the development of diffuse-type gastric carcinoma. A similar association between gastric-body-fold width and the location of the gastric carcinoma was found. Forty-four gastric carcinomas were located in the distal stomach (antrum/pylorus), 90 in the body and one in the gastric fundus. An increased fold width reduced the prevalence of gastric carcinomas in the distal stomach and increased those in the body (Fig. 2), which is well known to be a preferred location of diffuse-type gastric carcinoma. Thus, a correlation exists between the fold width and the incidence of diffuse-type carcinoma in the body (Fig. 3).

Production of mutagens in the stomach

Because enlarged-fold gastritis is characterized by a severe inflammation in the body region, endogenous inflammation-related mutagens may be the missing

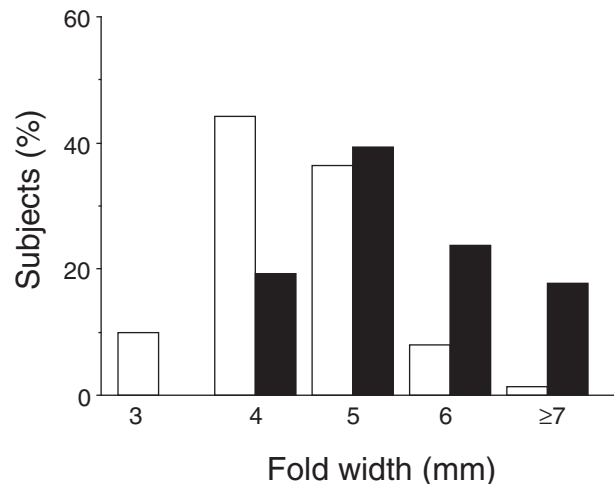


Figure 1 Distribution of gastric fold width among *Helicobacter pylori*-positive subjects (■) with or (□) without early gastric carcinoma. The data are expressed as a percentage of subjects in each fold width.

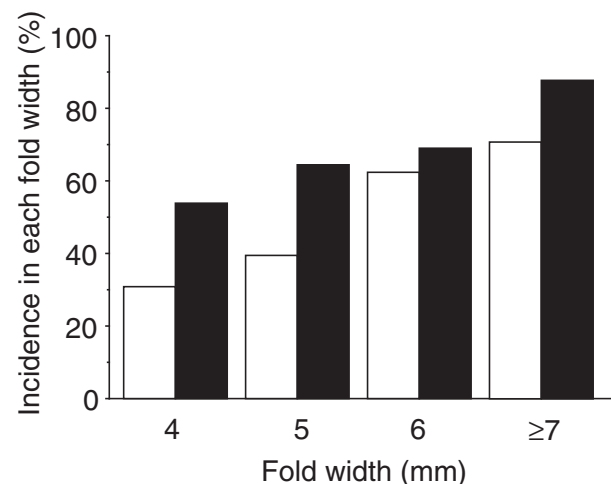


Figure 2 Prevalence of (□) diffuse-type carcinoma and (■) body carcinoma as a function of gastric fold width.

Table 2 Odds ratio for gastric carcinoma as a function of fold width

Fold width (mm)	No. of cases	No. of controls	Odds ratio (95% confidence interval)
≤ 4	26	77	1.0
5	53	51	3.1 (1.7–5.5)
6	32	11	8.6 (3.8–19.6)
≥ 7	24	2	35.5 (7.9–160.8)

link between enlarged-fold gastritis and carcinogenesis. The authors estimated and compared the mutagenicity of gastric juice in controls and patients with or without enlarged-fold gastritis. As shown in Figure 4, the mutagenicity determined by the Ames test using TA-98 or TA-100 in patients with enlarged-fold gastritis was significantly higher than that in *H. pylori*-negative controls and *H. pylori*-positive patients without enlarged folds. Furthermore, the mutagenicity was significantly decreased after the eradication of *H. pylori* (Fig. 5).

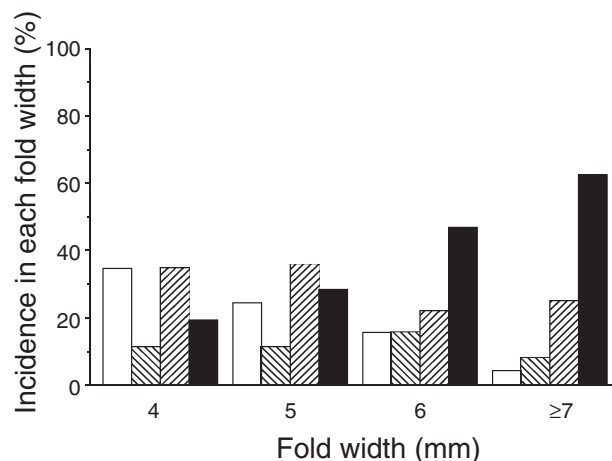


Figure 3 Histological type and location of early gastric carcinoma as a function of fold width. (□) Intestinal type in the distal stomach, (▨) diffuse type in the distal stomach, (▩) intestinal type in the body, (■) diffuse type in the body.

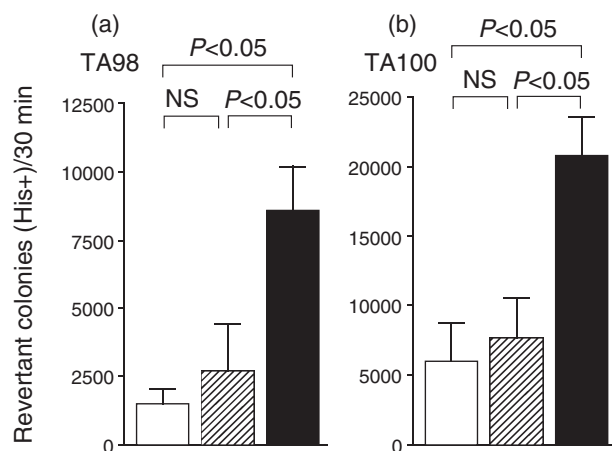


Figure 4 Mutagenicity of gastric juice assayed using Ames test and *Salmonella typhimurium* strain (a) TA-98 or (b) TA-100. The data are expressed as mean \pm SEM. NS, not significant. (□) *Helicobacter pylori*-negative controls ($n = 6$), (▨) *H. pylori*-positive without enlarged fold ($n = 7$), (■) enlarged-fold gastritis ($n = 15$).

Oxidative DNA damage in the gastric mucosa

As an indication of oxidative DNA damage, 8-OHdG levels in the gastric mucosa were examined in the gastric antral and body regions. In patients with enlarged-fold gastritis, the 8-OHdG levels in the antral mucosa were significantly higher than in *H. pylori*-negative controls (Fig. 6). However, no significant difference in antral 8-OHdG levels was found between non-enlarged- and enlarged-fold gastritis. In contrast, the 8-OHdG levels in the body mucosa from patients with enlarged-fold gastritis were significantly higher than in *H. pylori*-negative controls and *H. pylori*-positive patients without

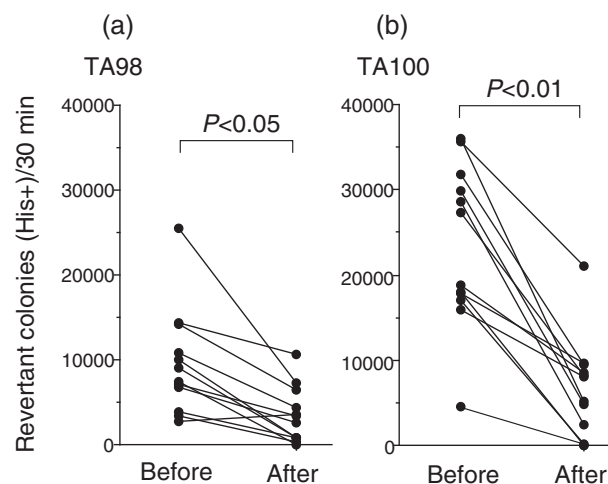


Figure 5 Changes in the mutagenicity of gastric juice from patients with enlarged-fold gastritis 2 months after eradication of *Helicobacter pylori*.

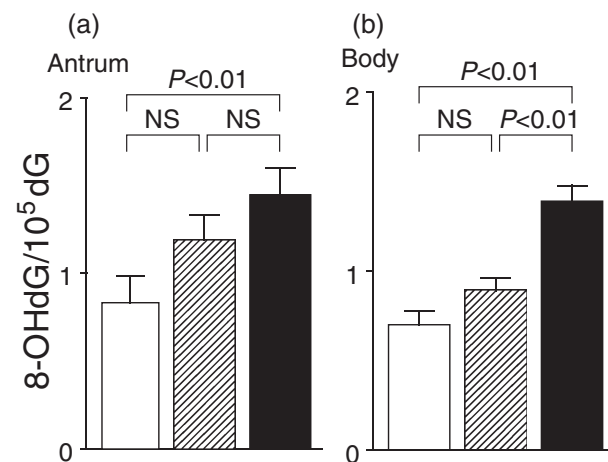


Figure 6 8-Hydroxydeoxyguanosine (8-OHdG) content of mucosal DNA samples from gastric antrum or body. The data are expressed as mean \pm SEM. NS, not significant. (□) *Helicobacter pylori*-negative controls ($n = 11$), (▨) *H. pylori*-positive without enlarged fold ($n = 9$), (■) enlarged-fold gastritis ($n = 13$).

enlarged-fold gastritis. Eradication of *H. pylori* significantly decreased the 8-OHdG levels in both the antral and the body mucosa of patients with enlarged-fold gastritis (Fig. 7).

Inflammatory cell infiltration

The authors have previously reported that mononuclear and polymorphonuclear infiltrates in the body mucosa, as well as in the antral mucosa, of patients with enlarged-fold gastritis were significantly more severe

than those in *H. pylori*-negative subjects. Inflammatory cell infiltration was more severe in the body mucosa of patients with enlarged-fold gastritis than in *H. pylori*-positive patients without enlarged folds, although these data were not statistically significant.¹⁴ In the present study, the relationship between the degree of inflammatory cell infiltration and the 8-OHdG content of gastric mucosal DNA among *H. pylori*-infected patients was examined. As shown in Figure 8, the degree of polymorphonuclear infiltration was significantly correlated with mucosal 8-OHdG levels in both the antral and the body regions. While severe infiltration of mononuclear cells seems to increase mucosal 8-OHdG content, these findings were not statistically significant (Fig. 9).

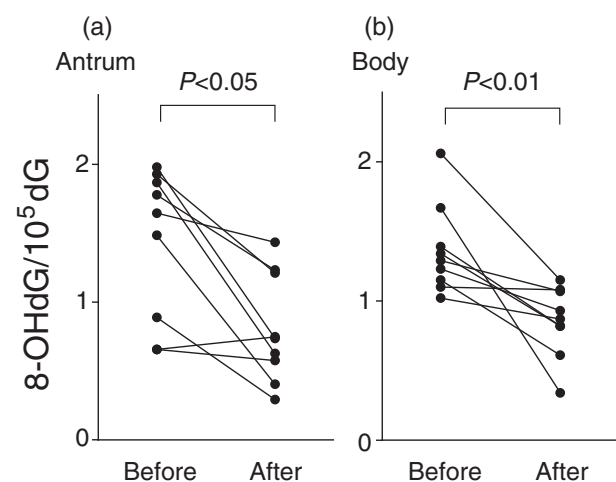


Figure 7 Changes in 8-hydroxydeoxyguanosine (8-OHdG) levels in patients with enlarged-fold gastritis 2 months after the eradication of *Helicobacter pylori*.

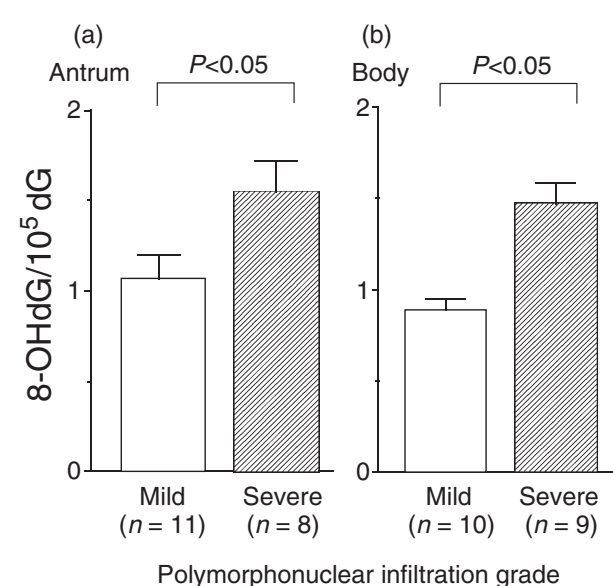


Figure 8 Relationship between polymorphonuclear infiltration and 8-hydroxydeoxyguanosine (8-OHdG) content of gastric mucosal DNA in *Helicobacter pylori*-infected patients. The data are expressed as mean \pm SEM.

DISCUSSION

The present study has shown that patients with early gastric carcinoma showed an increased prevalence of enlarged-fold gastritis. This suggests that enlarged-fold gastritis is associated with an increased risk of gastric carcinoma and that a careful examination should be made to detect gastric carcinoma.

Gastric carcinomas can be divided into two types according to Lauren's classification: intestinal and diffuse types. The epidemiology of gastric carcinoma suggests that these two types develop through distinct causal pathways. Patients with intestinal-type carcinoma are typically characterized by old age and tumor location in the lower third of the stomach, with a male predominance, whereas patients with diffuse-type carcinoma are younger, with the tumor location in the middle third of the stomach. Intestinal-type carcinomas frequently show atrophy and intestinal metaplasia of the

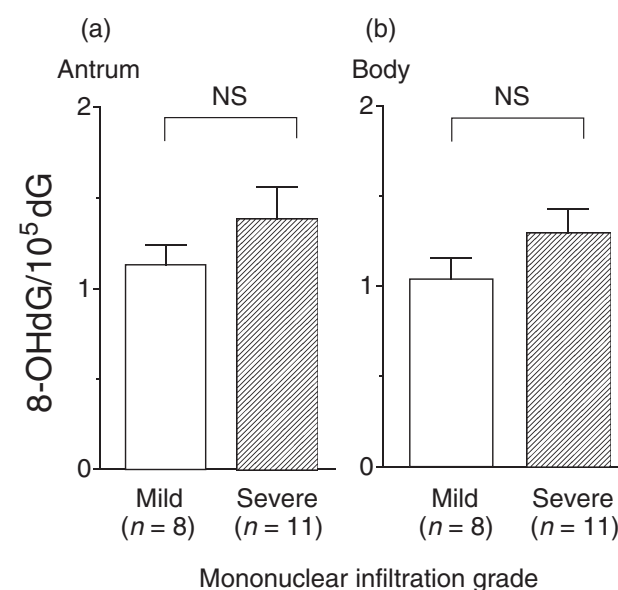


Figure 9 Relationship between mononuclear infiltration and 8-hydroxydeoxyguanosine (8-OHdG) content of gastric mucosal DNA in *Helicobacter pylori*-infected patients. The data are expressed as mean \pm SEM. NS, not significant.

surrounding non-neoplastic gastric mucosa. In contrast, diffuse-type carcinomas display such lesions less frequently. Thus intestinal- and diffuse-type gastric carcinoma may be epidemiologically distinct. Interestingly, in the present study, the thicker the body folds, the higher was the incidence of diffuse-type carcinoma in the gastric body. If the histogenesis of diffuse-type carcinoma is still somewhat obscure, the intestinal-type confirms the sequence: atrophic gastritis → intestinal metaplasia → dysplasia → neoplasia. In patients with enlarged-fold gastritis, mucosal atrophy and intestinal metaplasia were less frequent in the body mucosa, while this was not true for the antral mucosa.¹⁴ This condition may result in a preference for the development of diffuse-type carcinoma in the gastric body during the progression of mucosal atrophy in patients with enlarged-fold gastritis.

A plausible hypothesis for the missing link between *H. pylori* infection and gastric carcinogenesis involves endogenous inflammation-related mutagens, such as oxygen free radicals. *Helicobacter pylori*-related gastritis is accompanied by an increased oxygen free radical formation and peroxidative damage.¹⁹⁻²¹ The authors have previously reported that patients with enlarged-fold gastritis had extensive polymorphonuclear and mononuclear cells, particularly macrophages, with *H. pylori* colonization in their gastric body mucosa. Polymorphonuclear cells and macrophages produce oxygen free radicals that could cause DNA damage to the adjacent cells.²² Accumulation of oxidative DNA damage could lead to gene modifications of gastric epithelial cells that are mutagenic or carcinogenic. Gastric carcinoma patients showed significantly higher levels of 8-OHdG, the main DNA modifying agent produced by oxygen free radicals, in their tumor-adjacent tissues and tumor tissues than in normal tissues.²³ The present study showed that mutagenicity of the gastric juice of patients with enlarged-fold gastritis was significantly increased compared with *H. pylori*-negative controls and *H. pylori*-positive patients without enlarged folds. The authors further demonstrated an increase in the 8-OHdG content of mucosal DNA in patients with enlarged-fold gastritis. These results support the view that enlarged-fold gastritis is a risk factor for gastric carcinoma.

Baik *et al.* measured the 8-OHdG content in gastric mucosa from pediatric patients with or without *H. pylori* infection,²⁴ and showed that increased levels of 8-OHdG were observed in patients with *H. pylori* infection, compared with *H. pylori*-negative controls. The 8-OHdG content of gastric mucosal DNA is correlated with the disease activity of gastritis,²⁵ and is decreased after the eradication of *H. pylori*.^{26,27} In the present study, 8-OHdG levels in the body mucosa from patients with enlarged-fold gastritis were significantly higher than in *H. pylori*-negative controls and *H. pylori*-positive patients without enlarged-fold gastritis. Increased levels of mucosal 8-OHdG were found to correlate with the degree of infiltration of polymorphonuclear cells. While 8-OHdG levels in the antral mucosa of *H. pylori*-infected patients were significantly higher than in *H. pylori*-negative controls, no significant difference in antral 8-OHdG levels between non-enlarged- and

enlarged-fold gastritis was found. These findings suggest that the body mucosa of patients with enlarged-fold gastritis has an increased risk for gastric carcinoma among *H. pylori*-infected subjects. This may explain the increased prevalence of gastric body carcinoma with increasing fold width.

In conclusion, the present study has demonstrated that enlarged-fold gastritis may be a major risk factor for gastric carcinoma among *H. pylori*-infected persons. Enlarged folds, severe inflammation, marked acid inhibition, increased mutagen production, and increased 8-OHdG content observed in patients with enlarged-fold gastritis are all reversible after the eradication of *H. pylori*. The authors propose that *H. pylori*-infected persons with enlarged-fold gastritis are a potential population for the prevention of gastric carcinoma via the use of antibiotics.

ACKNOWLEDGMENTS

This work was supported in part by a grant-in-aid for Y Shinomura (grant No.08670586), a grant-in-aid for S Kanayama (grant No.08670582) and a grant-in-aid for Y Higashimoto (grant No.08670584) from the Ministry of Education, Science, and Culture of Japan.

REFERENCES

- Misiewicz JJ, Tytgat GNJ, Goodwin CS *et al.* The Sydney system: a new classification of gastritis. *Working Party Reports of the World Congresses of Gastroenterology; 1990 August 26-31; Sydney*. Melbourne: Blackwell Science, 1990; 1-10.
- Price AB. The Sydney system: histological division. *J. Gastroenterol. Hepatol.* 1991; **6**: 209-22.
- Press AJ. Practical significance of gastric rugal folds. *Am. J. Roentgenol. Radium Ther. Nucl. Med.* 1975; **125**: 172-83.
- Yasunaga Y, Shinomura Y, Kanayama S *et al.* Improved fold width and increased acid secretion after eradication of the organism in *Helicobacter pylori* associated enlarged fold gastritis. *Gut* 1994; **35**: 1571-4.
- Yasunaga Y, Shinomura Y, Kanayama S *et al.* Increased production of interleukin 1 β and hepatocyte growth factor may contribute to foveolar hyperplasia in enlarged fold gastritis. *Gut* 1996; **39**: 787-94.
- Rohrmann CA Jr, Seaman WB. Nonneoplastic lesions of the stomach. In: Stamathis G, ed. *Alimentary Tract Radiology*. St Louis: Mosby, 1989; 551-93.
- Komorowski RA, Caya JG. Hyperplastic gastropathy: clinicopathologic correlation. *Am. J. Surg. Pathol.* 1991; **15**: 577-85.
- Stolte M, Bätz CH, Eidt S. Giant fold gastritis - a special form of *Helicobacter pylori* associated gastritis. *Z. Gastroenterol.* 1993; **31**: 289-93.
- Morrison S, Dahms BB, Hoffenberg E, Czinn SJ. Enlarged gastric folds in association with *Campylobacter pylori* gastritis. *Radiology* 1989; **171**: 819-21.
- Stolte M, Bätz CH, Bayerdörffer E, Eidt S. *Helicobacter pylori* eradication in the treatment and differential

- diagnosis of giant folds in the corpus and fundus of the stomach. *Z. Gastroenterol.* 1995; **33**: 198–201.
- 11 Avunduk C, Navab F, Hamp F, Coughin B. Prevalence of *Helicobacter pylori* infection in patients with large gastric folds: evaluation and follow-up with endoscopic ultrasound before and after antimicrobial therapy. *Am. J. Gastroenterol.* 1995; **90**: 1969–73.
 - 12 IARC Working Group on the Evaluation of Carcinogenic Risks to Humans. *Helicobacter pylori*. In: *Schistosomes, Liver Flukes and Helicobacter pylori: Views and Expert Opinions of an IARC Working Group on the Evaluation of Carcinogenic Risks to Humans*. Lyon: IARC, 1994; 177–240.
 - 13 Uemura N, Okamoto S, Yamamoto S *et al.* *Helicobacter pylori* infection and the development of gastric cancer. *N. Engl. J. Med.* 2001; **345**: 784–9.
 - 14 Murayama Y, Miyagawa J, Shinomura Y *et al.* Morphological and functional restoration of parietal cells in *Helicobacter pylori*-associated enlarged fold gastritis after eradication. *Gut* 1999; **45**: 653–61.
 - 15 Yasunaga Y, Shinomura Y, Kanayama S *et al.* Mucosal interleukin-1 beta production and acid secretion in enlarged fold gastritis. *Aliment. Pharmacol. Ther.* 1997; **11**: 801–9.
 - 16 Rauws EA, Langenberg W, Houthoff HJ, Zanen HC, Tytgat GN. *Campylobacter pyloridis*-associated chronic active antral gastritis. A prospective study of its prevalence and the effects of antibacterial and antiulcer treatment. *Gastroenterology* 1988; **94**: 33–40.
 - 17 Marshall BJ, Warren JR, Francis GJ, Langton SR, Goodwin CS, Blincow ED. Rapid urease test in the management of *Campylobacter pyloridis*-associated gastritis. *Am. J. Gastroenterol.* 1987; **82**: 200–10.
 - 18 Nakajima M, Takeuchi T, Morimoto K. Determination of 8-hydroxydeoxyguanosine in human cells under oxygen-free conditions. *Carcinogenesis* 1996; **17**: 787–91.
 - 19 Davies GR, Simmonds NJ, Stevens TR *et al.* *Helicobacter pylori* stimulates antral mucosal reactive oxygen metabolite production in vivo. *Gut* 1994; **35**: 179–85.
 - 20 Davies GR, Banatvala N, Collins CE *et al.* Relationship between infective load of *Helicobacter pylori* and reactive oxygen metabolite production in antral mucosa. *Scand. J. Gastroenterol.* 1994; **29**: 419–24.
 - 21 Farinati F, Della Libera G, Cardin R *et al.* Gastric anti-oxidant, nitrites, and mucosal lipoperoxidation in chronic gastritis and *Helicobacter pylori* infection. *J. Clin. Gastroenterol.* 1996; **22**: 275–81.
 - 22 Correa P. *Helicobacter pylori* as a pathogen and carcinogen. *J. Physiol. Pharmacol.* 1997; **48** (Suppl. 4): 19–24.
 - 23 Lee BM, Jang JJ, Kim HS. Benzo[a]pyrene diol-epoxide-I-DNA and oxidative DNA adducts associated with gastric adenocarcinoma. *Cancer Lett.* 1998; **125**: 61–8.
 - 24 Baik SC, Youn HS, Chung MH *et al.* Increased oxidative DNA damage in *Helicobacter pylori*-infected human gastric mucosa. *Cancer Res.* 1996; **56**: 1279–82.
 - 25 Farinati F, Cardin R, Degan P *et al.* Oxidative DNA damage accumulation in gastric carcinogenesis. *Gut* 1998; **42**: 351–6.
 - 26 Hahm KB, Lee KJ, Choi SY *et al.* Possibility of chemoprevention by the eradication of *Helicobacter pylori*: oxidative DNA damage and apoptosis in *H. pylori* infection. *Am. J. Gastroenterol.* 1997; **92**: 1853–7.
 - 27 Pignatelli B, Bancel B, Plummer M, Toyokuni S, Patricot LM, Ohshima H. *Helicobacter pylori* eradication attenuates oxidative stress in human gastric mucosa. *Am. J. Gastroenterol.* 2001; **96**: 1758–66.