조기위암 내시경 치료 후 추적관찰

성균관대학교 의과대학 내과 이준행

조기위암 내시경 치료 후 extragastric recurrence

성균관대학교 의과대학 내과 이준행

EMR/ESD data analysis at SMC

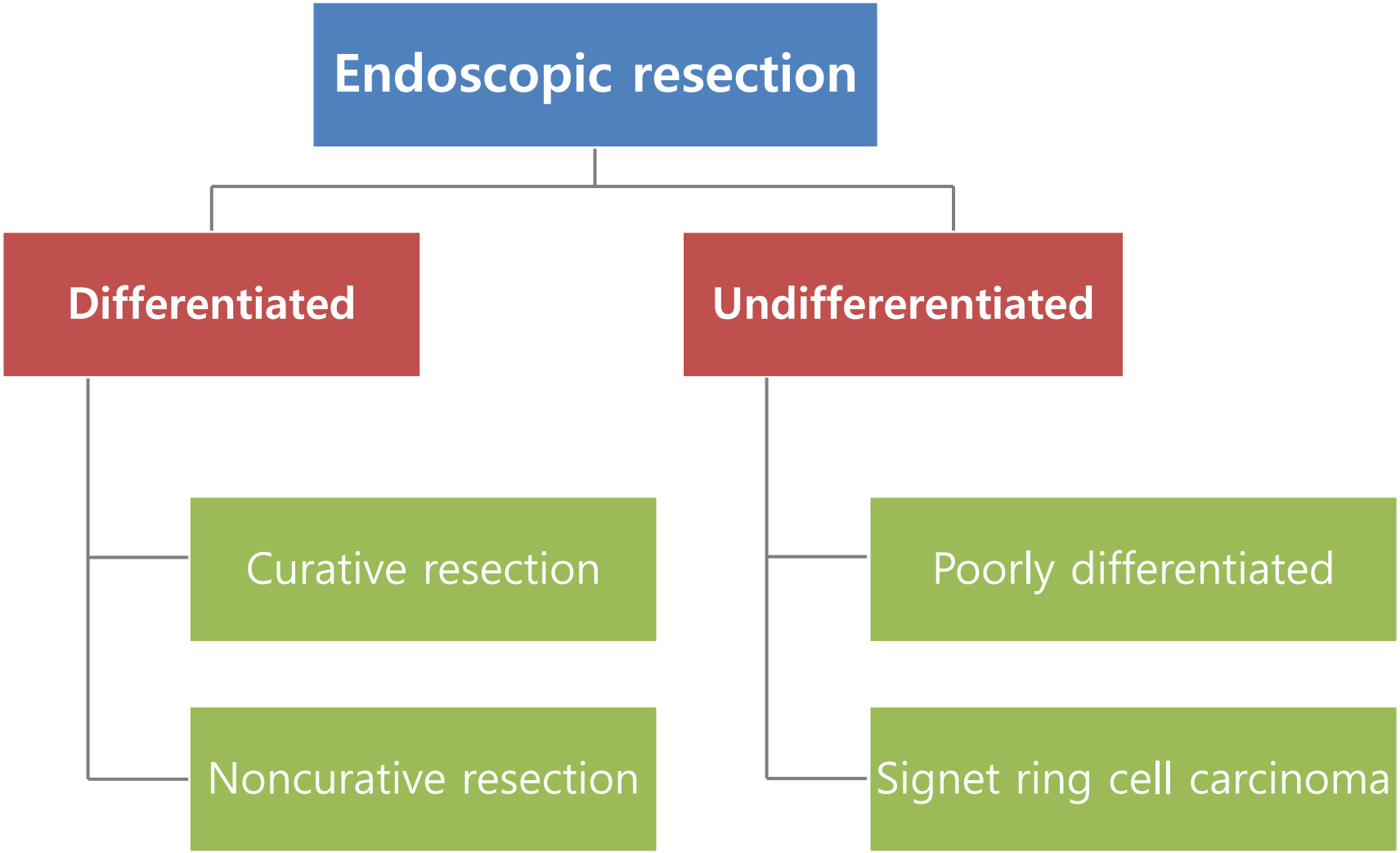

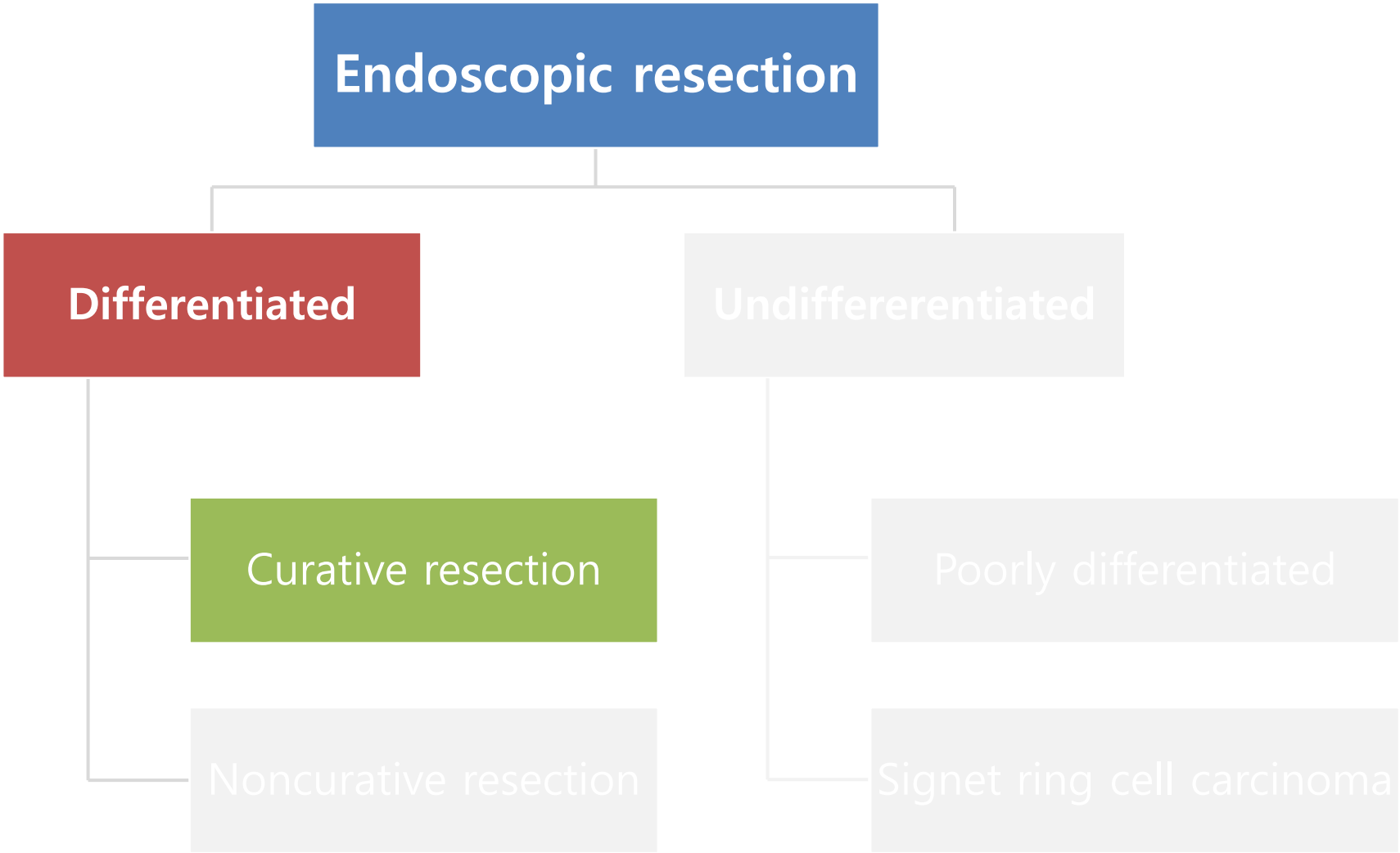
Endoscopic resection
Differentiated
Undiffererentiated
Curative resection
Noncurative resection
Poorly differentiated
Signet ring cell carcinoma

Study population

- EGCs treated by ESD at Samsung Medical Center
- 1,838 patients with 1,889 differentiated-type EGCs
- November 2003 – May 2011
- Censoring date: May 2014
- **Differentiated-type EGC**
  - Well or moderately differentiated or papillary EGC
  - According to the quantitatively predominant histologic type
  - Differentiated-type EGC > 50%

Min BH (SMC). Endoscopy 2015

Immediate outcome measures

- 1,838 cases with 1,889 EGCs treated by ESD
- Patients enrollment: November 2003 - May 2011

- En bloc resection rate: 96.9%
- R0 resection rate: 94.0%
- En bloc and R0 resection rate: 92.2%
- **Curative resection: 81.5%**

  (1,539 EGCs in 1,497 patients / 1,838 EGCs in 1,889 patients)
- Bleeding: 4.1%, perforation: 3.2%

Min BH (SMC). Endoscopy 2015

Overall-survival

- 1,306 curative ESDs from December 2003 to May 2011

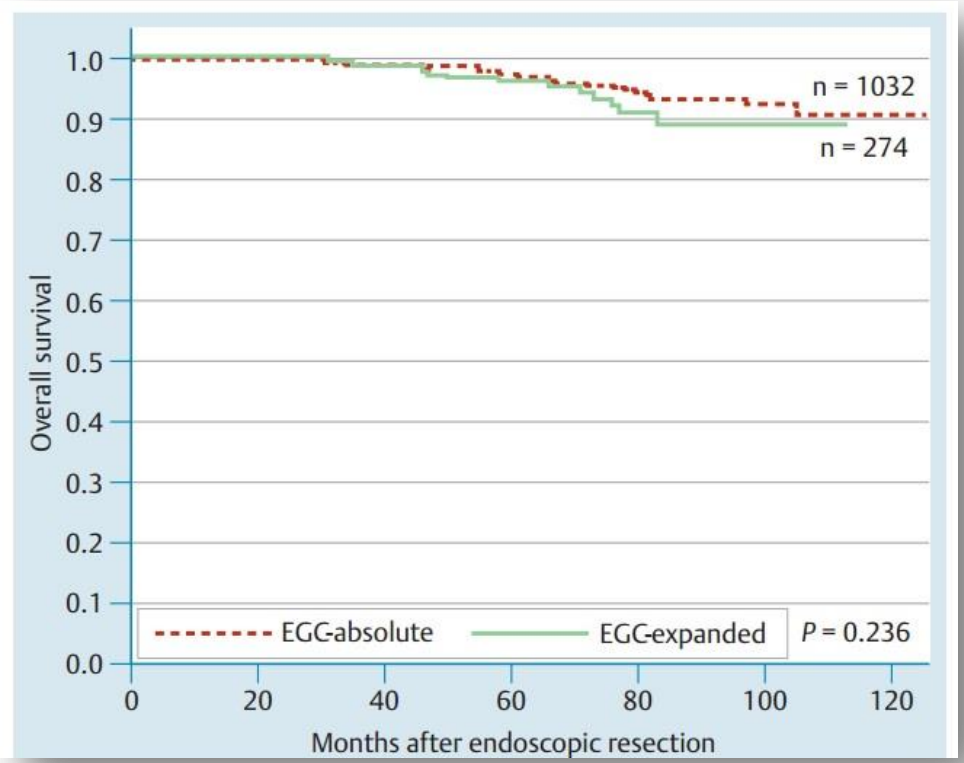

Min BH (SMC). Endoscopy 2015

Long-term outcome

- 1,306 curative ESDs from December 2003 to May 2011

- Median follow-up: 61 months (range 17-122)
- **Local recurrence: 0.08% (1/1,306)**
- Metachronous recurrence: 3.6% (47/1,306)
  - Definition of metachronous recurrence: at least 12 months after ER
- **Extragastric recurrence: 0.15% (2/1,306)**
- 5-year overall survival
  - Absolute indication: 97.3%
  - Expanded indication: 96.4%

Min BH (SMC). Endoscopy 2015

2 extragastric recurrences (0.15%)

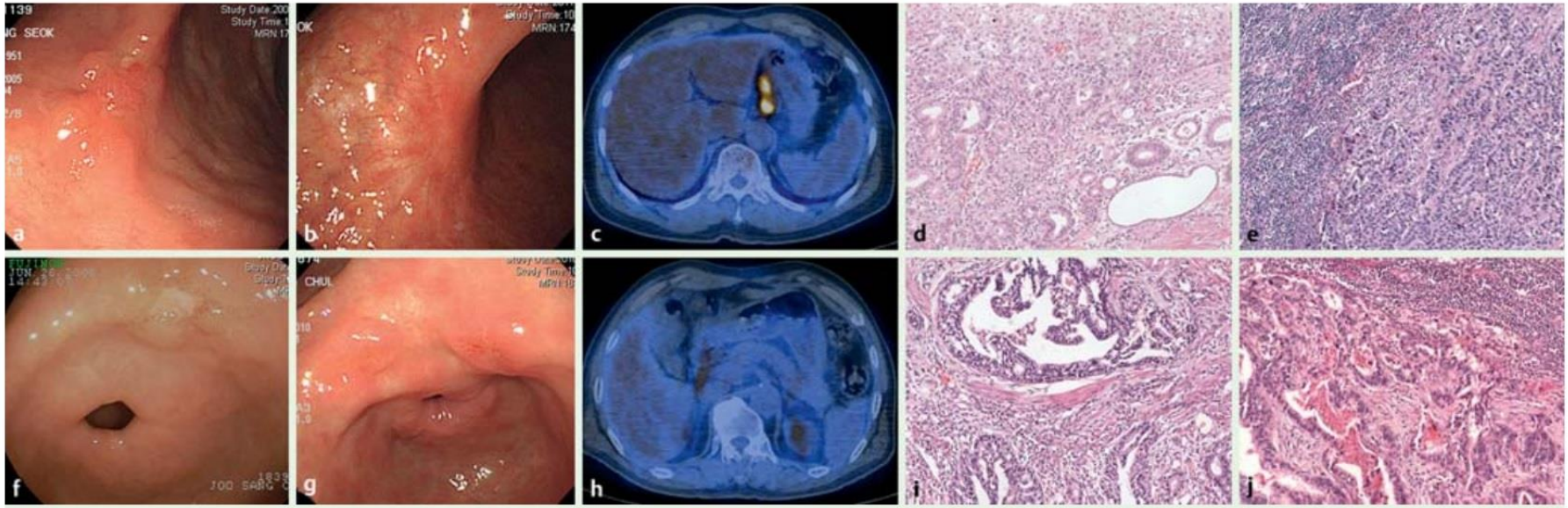

Fig. 4 Two cases of extragastric recurrence after curative endoscopic submucosal dissection (ESD) for early gastric cancer. **a–e** Patient #1 in **Table 3** (Present study): the cancer met the absolute indication and was treated with curative ESD, and was located at the angle. **a** Esophagogastroduodenoscopy (EGD) appearance of lesion before ESD. **b** EGD view 61 months after ESD. **c** 18^F-fluorodeoxyglucose (FDG) positron emission tomography-computed tomography (PET-CT) image 61 months after ESD; hypermetabolic lesions are seen in perigastric lymph nodes. **d** Histological appearance of ESD specimen (hematoxylin and eosin [H&E], × 200). **e** Histological appearance of lymph node with cancer cell infiltration (H&E, × 200). **f–j** Patient #2 in **Table 3** (Present study): the cancer met the expanded indication and was treated with curative ESD, and was located at the antrum. **f** EGD appearance of lesion before ESD. **g** EGD view 48 months after ESD. **h** 18^F-FDG PET-CT image 48 months after ESD; hypermetabolic lesions are seen in lymph nodes around the common hepatic artery. **i** Histological appearance of ESD specimen (H&E, × 200). **j** Histological appearance of lymph node with cancer cell infiltration (H&E, × 200).

Min BH (SMC). Endoscopy 2015

Pattern of recurrences (n=1,460)

- Complete resection, absolute + expanded
- Differentiated type histology
- EMR or ESD from April 2000 - May 2011

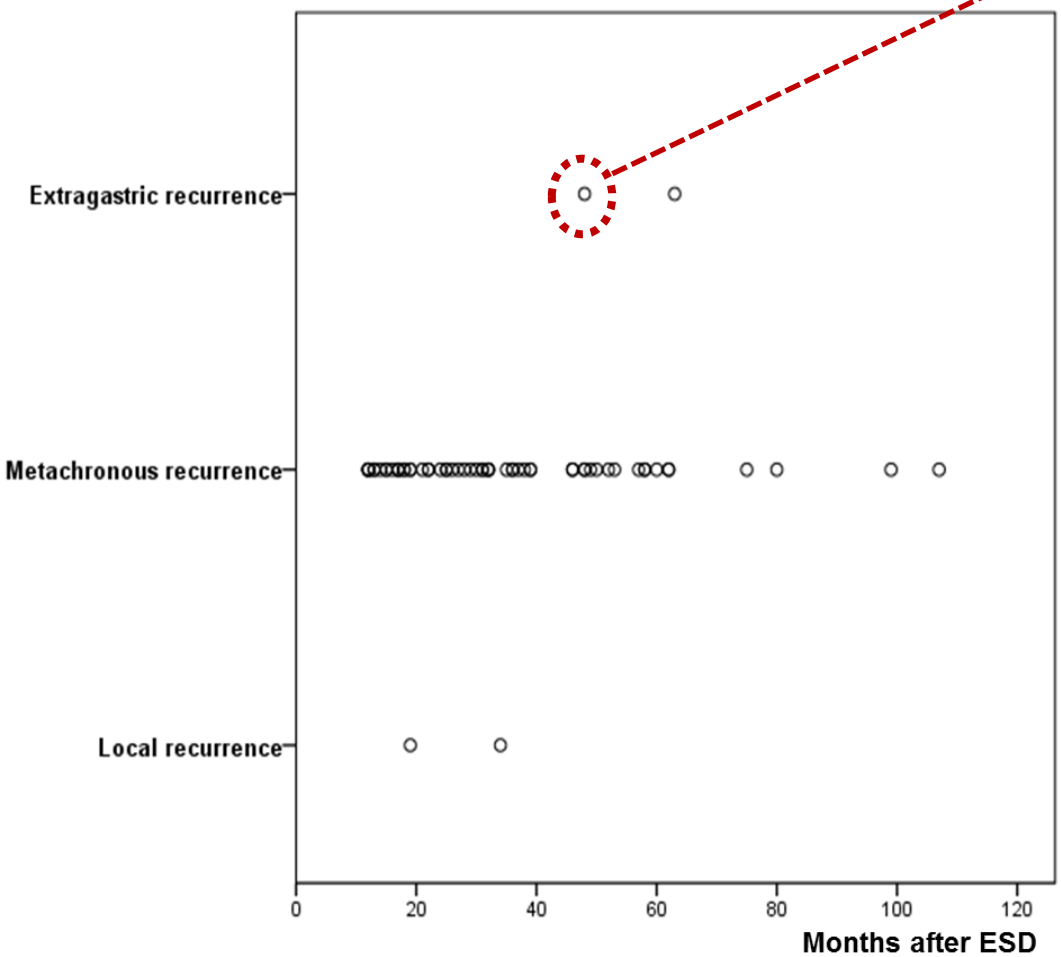

The only one unhappy outcome (lymph nodes and peritoneal recurrence).

Pattern of extragastric recurrence

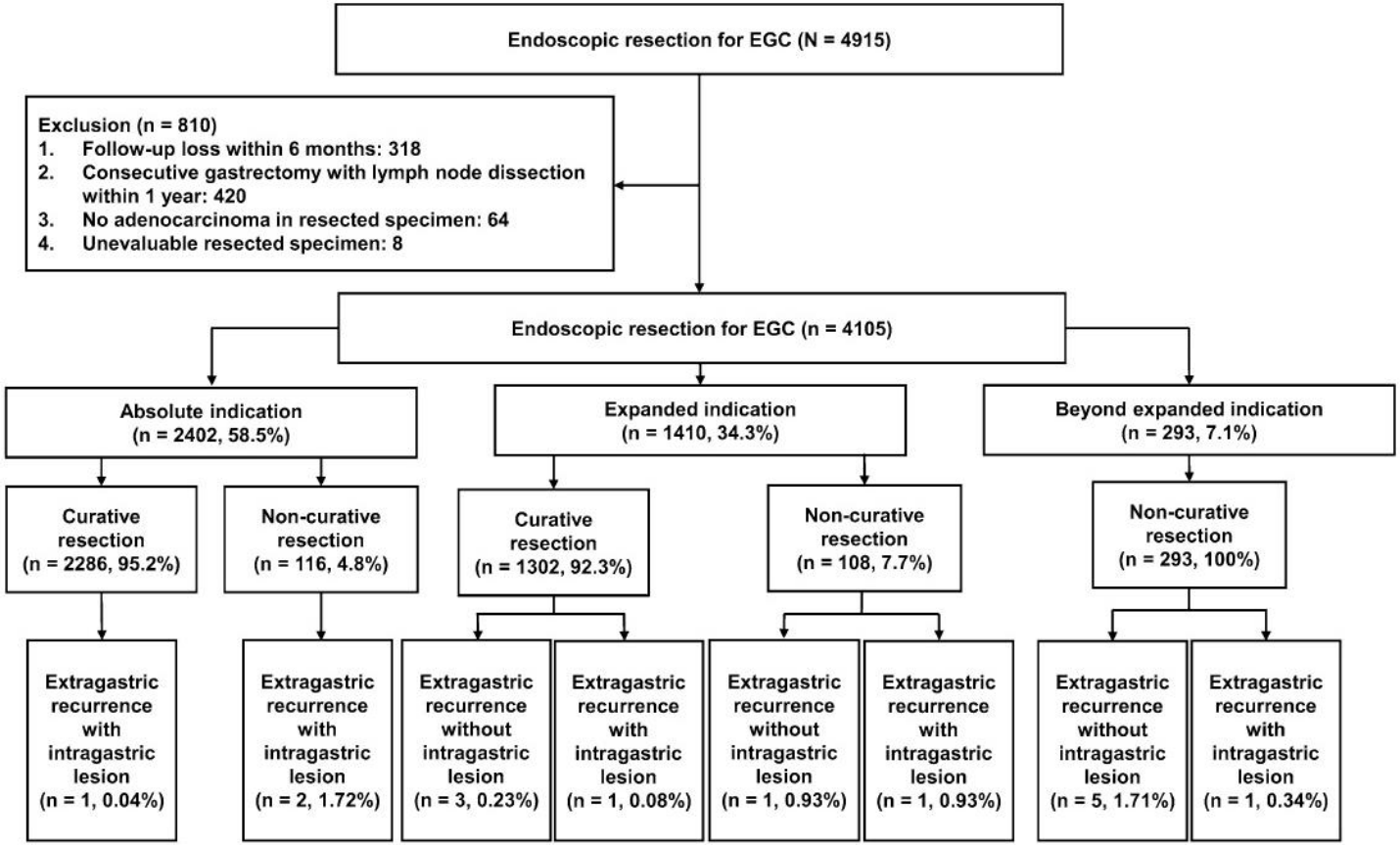

Fig. 1 Flowchart for the enrolled patients who underwent endoscopic resection for early gastric cancer (*EGC*): incidence and pattern of extragastric recurrence

Lee S (**AMC**). Gastric Cancer 2017;20:843-852

EGD and CT is complementary

Table 2 Extragastric recurrence patterns and detection methods according to the recurrence pattern after endoscopic resection of early gastric cancer

Detection methods	Pattern of recurrence			
	Regional LN recurrence ($n = 11$)		Distant recurrence ($n = 4$)	
	Without intragastric lesion	With intragastric lesion	Without intragastric lesion	With intragastric lesion
EGD alone	0	4 (26.7%)	0	0
CT alone	7 (46.7%)	0	2 (13.3%)	0
Both EGD and CT	0	0	0	2 (13.3%)

CT computed tomography, *EGD* esophagogastroduodenoscopy, *LN* lymph node

Lee S (**AMC**). Gastric Cancer 2017;20:843-852

Table 3 Treatment outcomes among the study patients with extragastric recurrence

Patient	Indication	Curability	Recurrence type	Treatment for recurrence	Outcome
1	Absolute	CR	Regional LN recurrence with metachronous AGC	STG	Dead (56.2 months)
2	Absolute	NCR	Regional LN recurrence with metachronous EGC	STG	Alive (108.7 months)
3	Absolute	NCR	Distant recurrence with metachronous EGC (liver, lung)	Refusal	Dead (3.6 months)
4	Expanded	CR	Regional LN recurrence	TG + CTx	Alive (34 months)
5	Expanded	CR	Regional LN recurrence	TG + CTx	Alive (79 months)
6	Expanded	CR	Regional LN recurrence	CTx	Alive (68 months)
7	Expanded	NCR	Regional LN recurrence	STG	Alive (135 months)
8	Expanded	NCR	Regional LN recurrence with metachronous EGC	STG	Alive (164.6 months)
9	Expanded	CR	Distant and regional LN recurrence with metachronous EGC (left adrenal gland)	CTx	Dead (34.8 months)
10	Beyond expanded	NCR	Regional LN recurrence	STG	Alive (19 months)
11	Beyond expanded	NCR	Regional LN recurrence	CTx	Dead (33 months)
12	Beyond expanded	NCR	Regional LN recurrence	Refusal	Dead (9 months)
13	Beyond expanded	NCR	Regional LN recurrence with locally recurred AGC	TG + CTx	Dead (31.7 months)
14	Beyond expanded	NCR	Distant and regional LN recurrence (liver)	CTx	Dead (11 months)
15	Beyond expanded	NCR	Distant and regional LN recurrence (peritoneal seeding)	Refusal	Dead (3 months)

Lee S (**AMC**). Gastric Cancer 2017;20:843-852

7 more extragastric recurrences after the publication

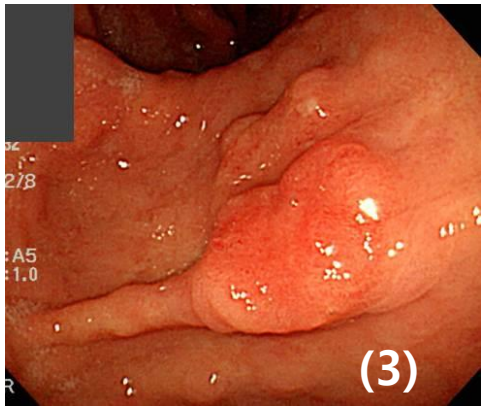

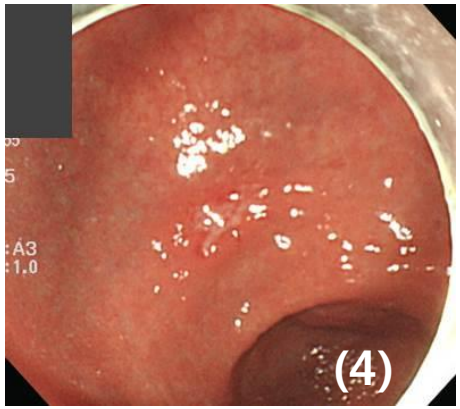

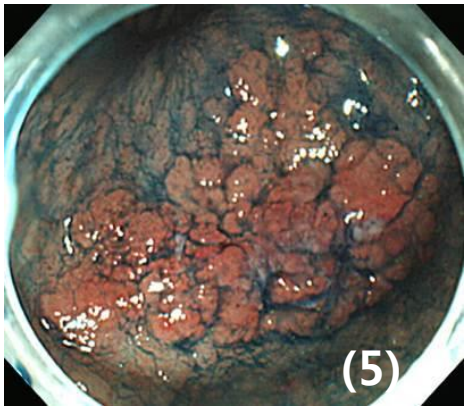

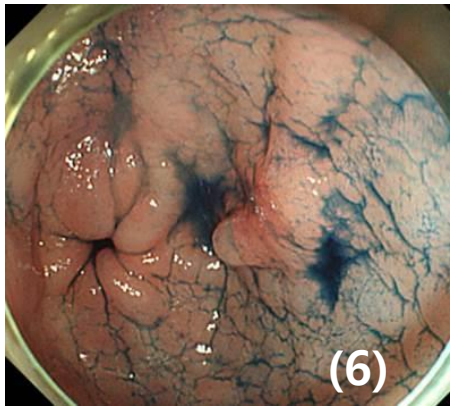

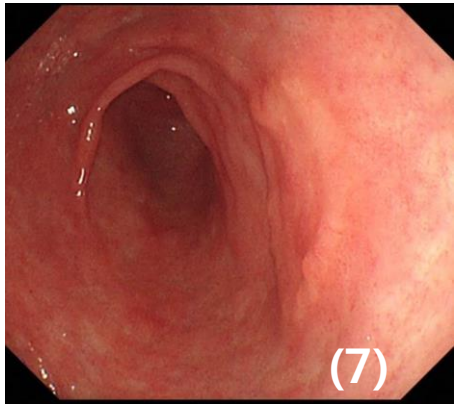

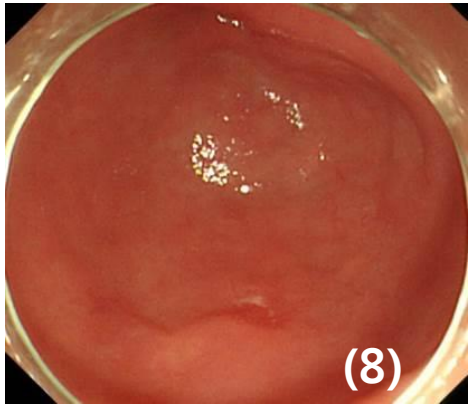

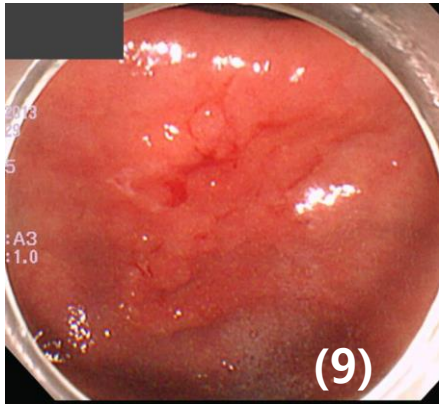

#7. M/D, 16mm, SM 400um

- Enlarged lymph node at CT, 17 months after ESD

#7. M/D, 16mm, SM 400um

- Enlarged lymph node at CT, 17 months after ESD

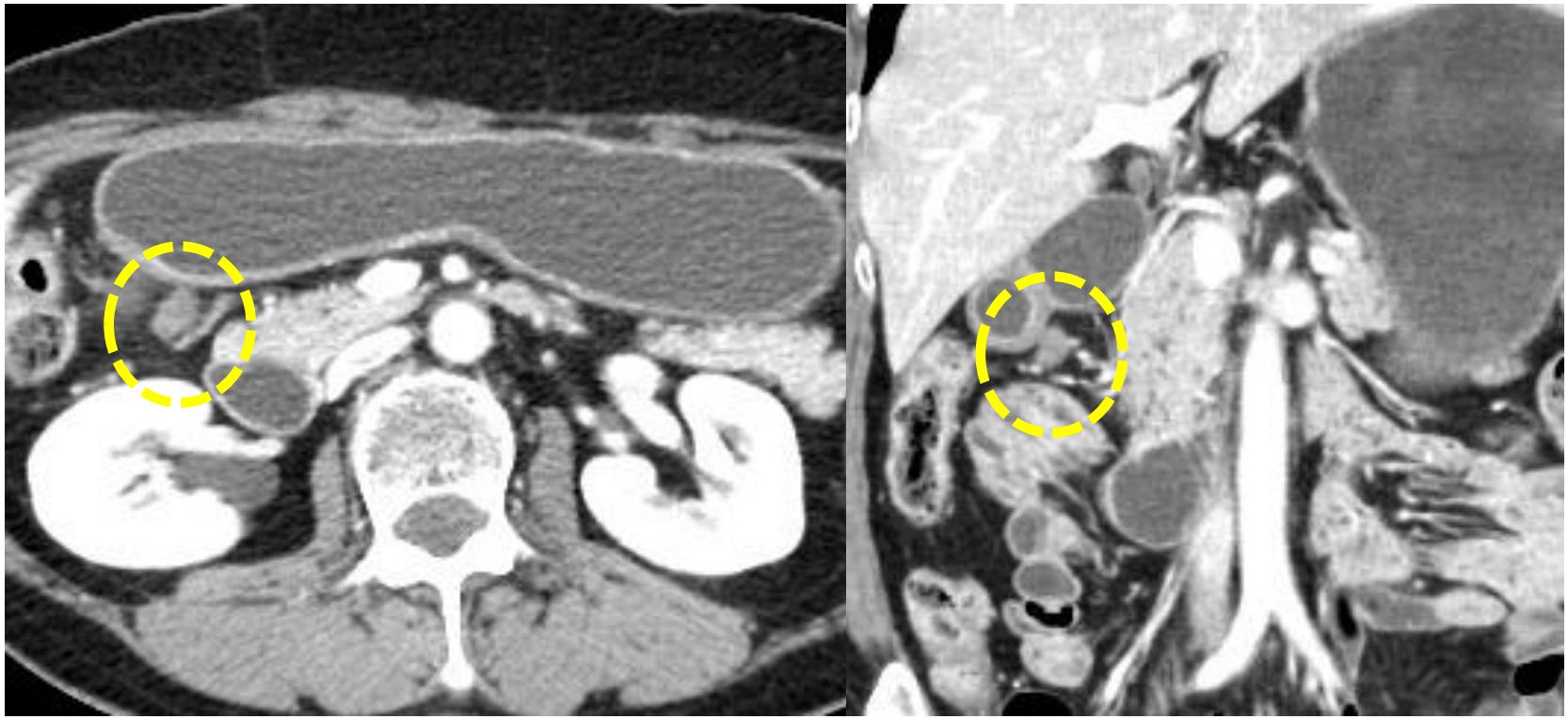

#7: PET positive였지만 SUV=2.2로 매우 faint한데 결론은 암으로 주었음. 아마도 CT 사진 참조한 것 같은

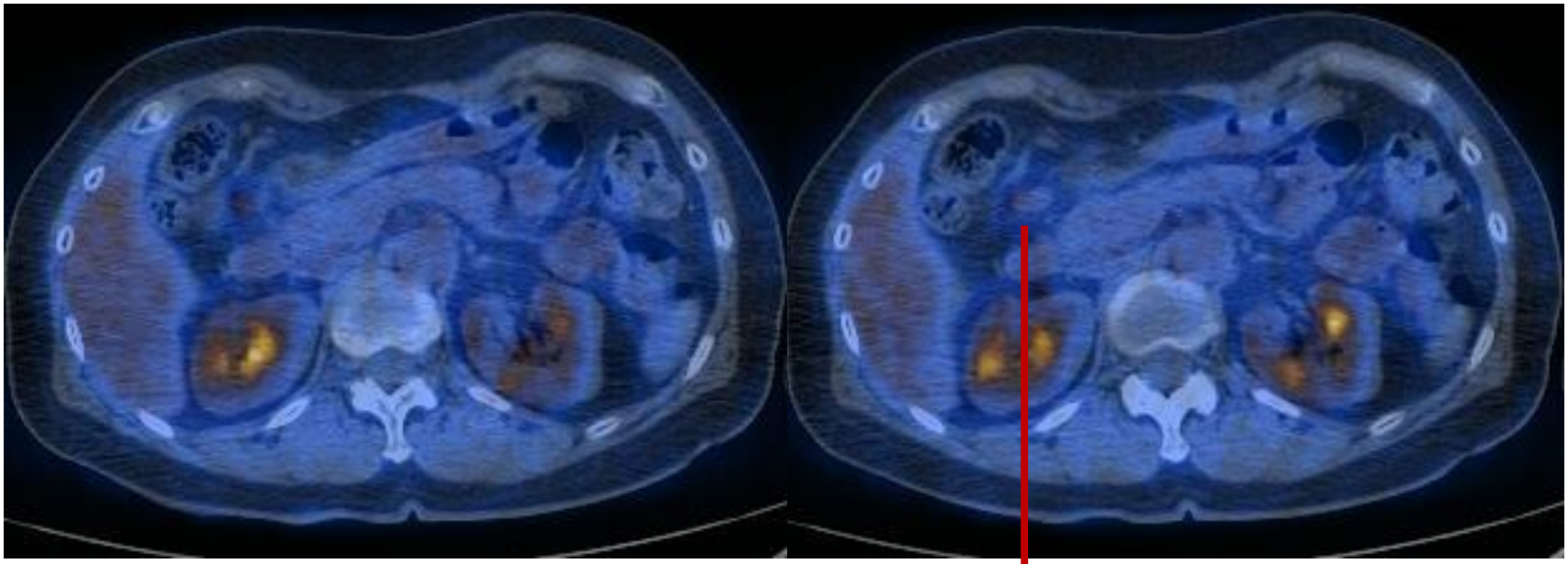

이게 positive라니 믿어집니까?

#7. M/D, 16mm, SM 400um

- Enlarged lymph node at CT, 17 months after ESD

- Stomach, subtotal gastrectomy: Status ESD
- Gastric location: cannot be determined (no residual tumor)
- Lymph node metastasis : metastasis to 1 out of 22 regional lymph nodes (pN1) (perinodal extension: present)

  (**1/22: "LN#6" for frozen section-1, 1/1**; "3,5", 0/3; "4,6", 0/6; "5", 0/0; "6", 0/3; "7", 0/2; "9", 0/2; "8a", 0/2; "11p", 0/2; "12a", 0/1; "4sb", 0/0; "1", 0/0)

#9. Systemic recurrence after 5 years

- 38x22mm, M/D, LP, RM (-), L/V (-)

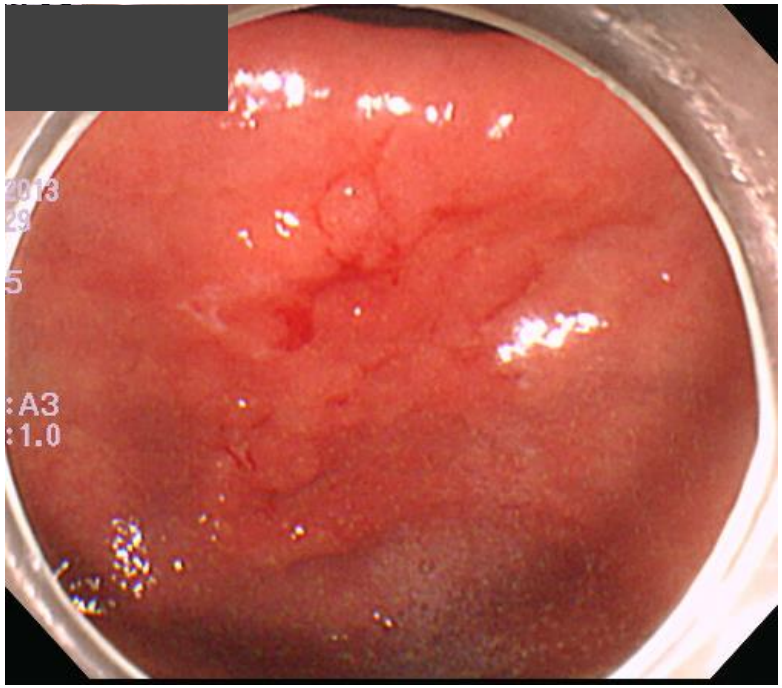

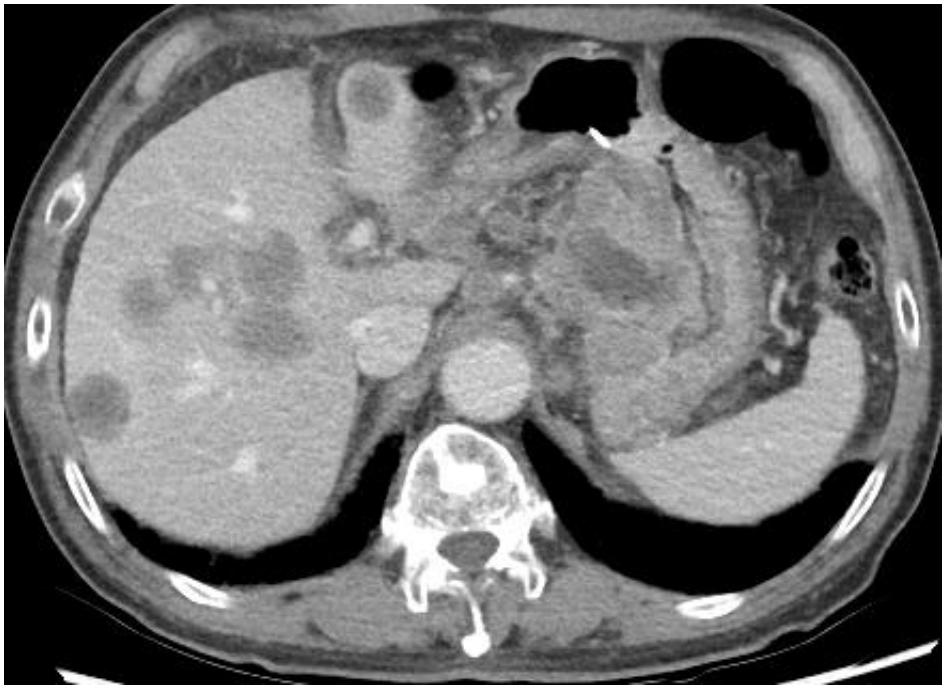

5 years later

몇 년 전 중국에서 ESD
→ 최근 국내에서 간전이가 발견

수 년 전 타 병원에서 ESD
→ 다발성 재발

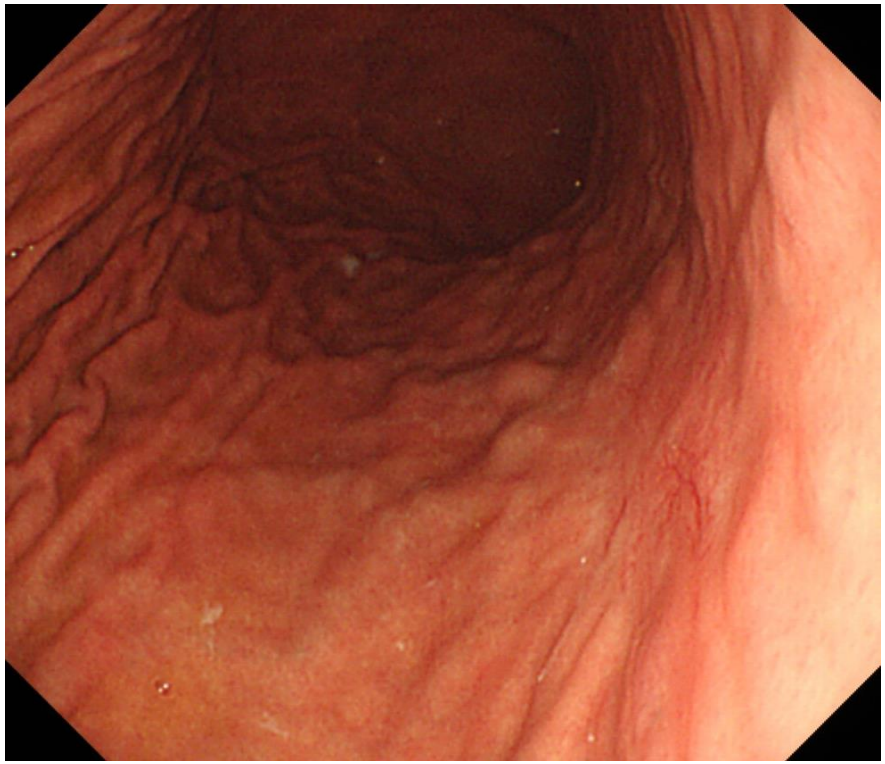

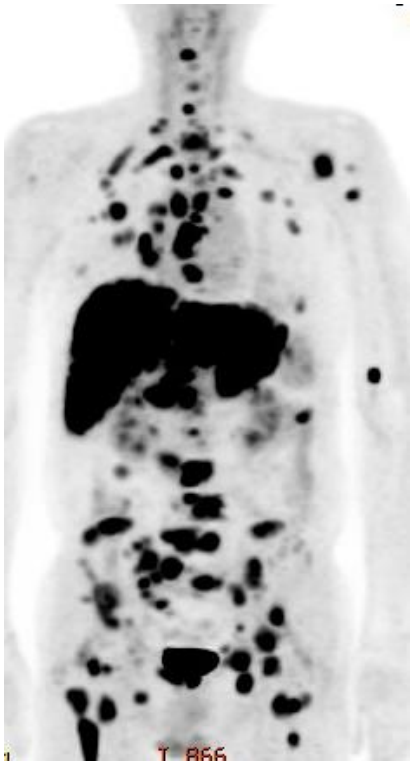

다발성 재발 당시 내시경에서는 이상 소견 없음

ESD 후 내시경 소견

성균관대학교 의과대학 내과 이준행

문제 의식

- 위궤양, 조기 위암, 진행 위암의 내시경 소견은 배운다.
- 위암 수술 후 소견은 가끔 배운다.
- 위암 내시경 시술 후 소견은 배운 적이 없다.
- 관찰과 조직검사에 대한 가이드라인이 없다.

전형적 증례

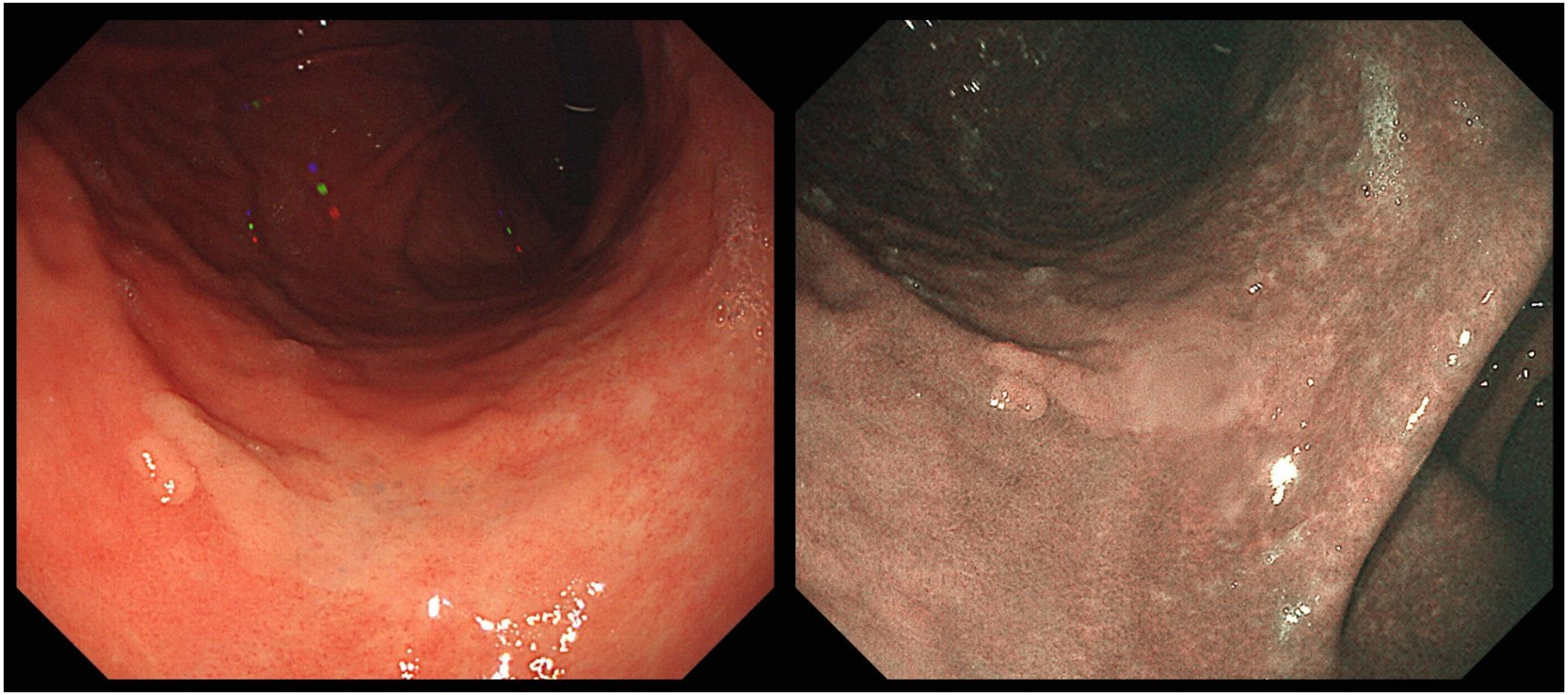

ESD – M/D, 18mm, LP, RM (-), L/V (-)

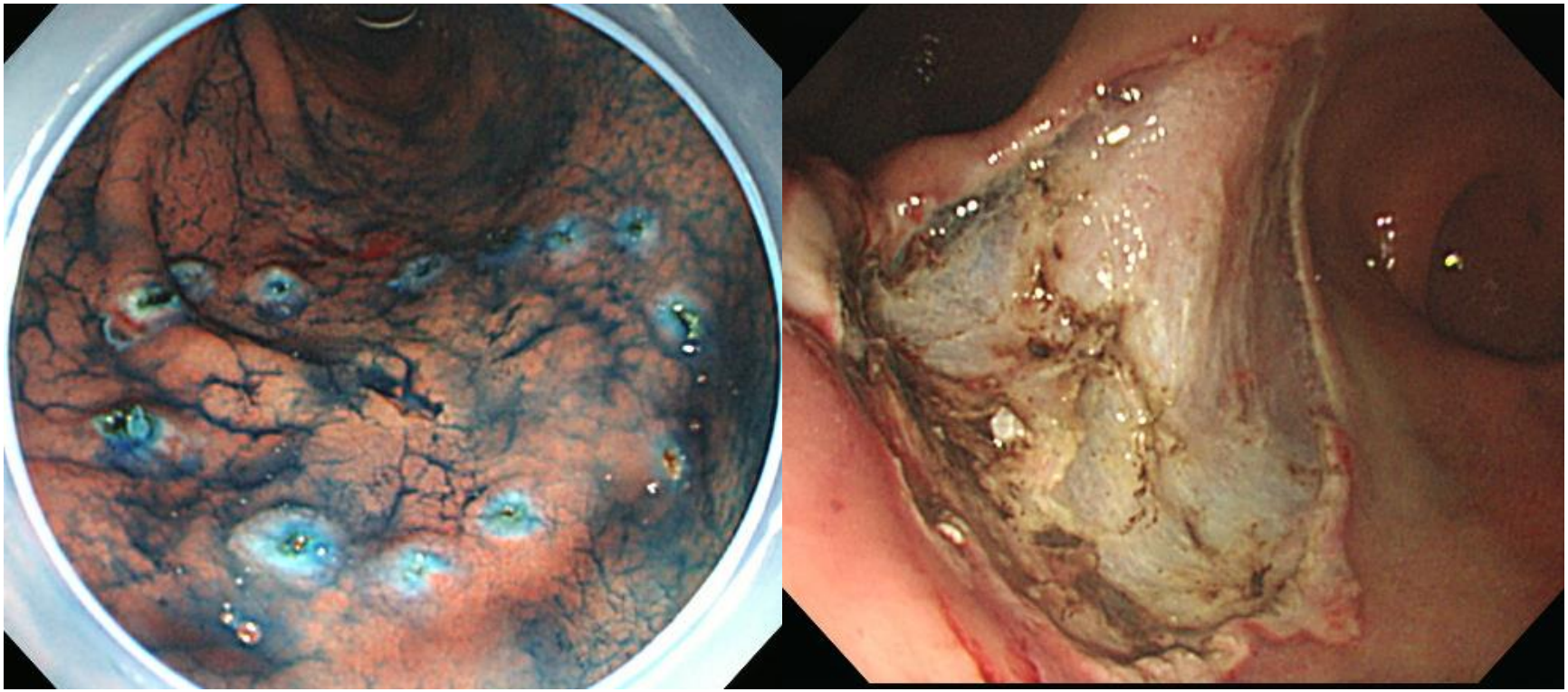

추적 내시경 소견

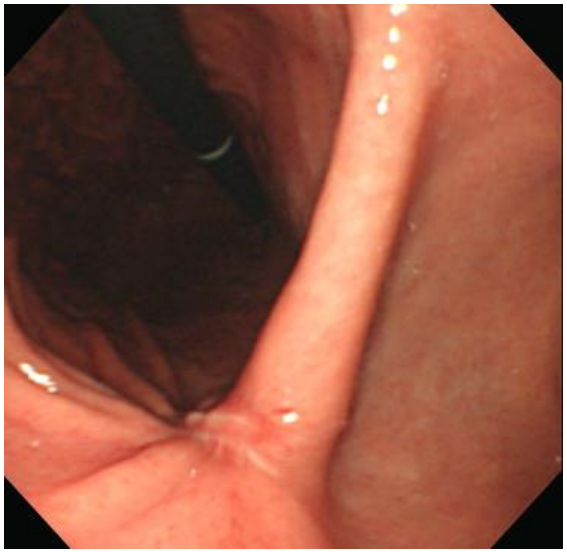

2달 후

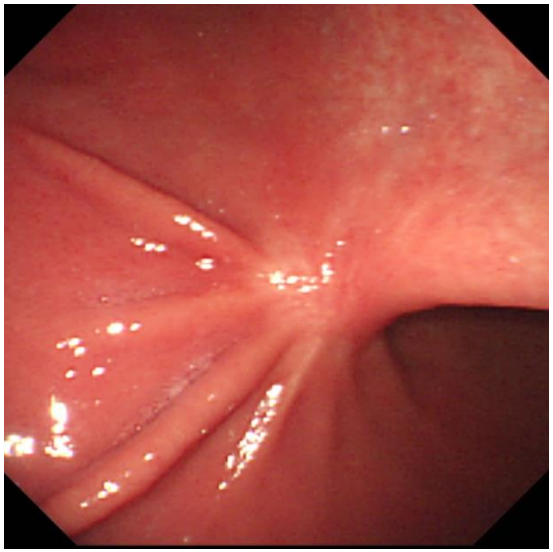

6달 후

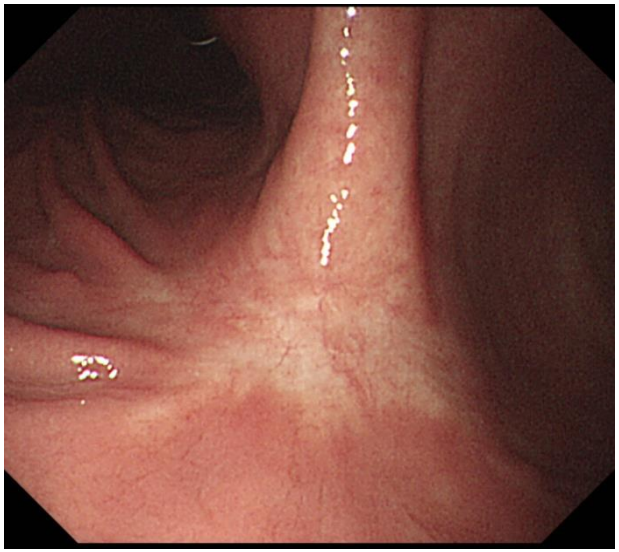

3년 후

만약 중간에 검사해보면 어떻게 보일까?

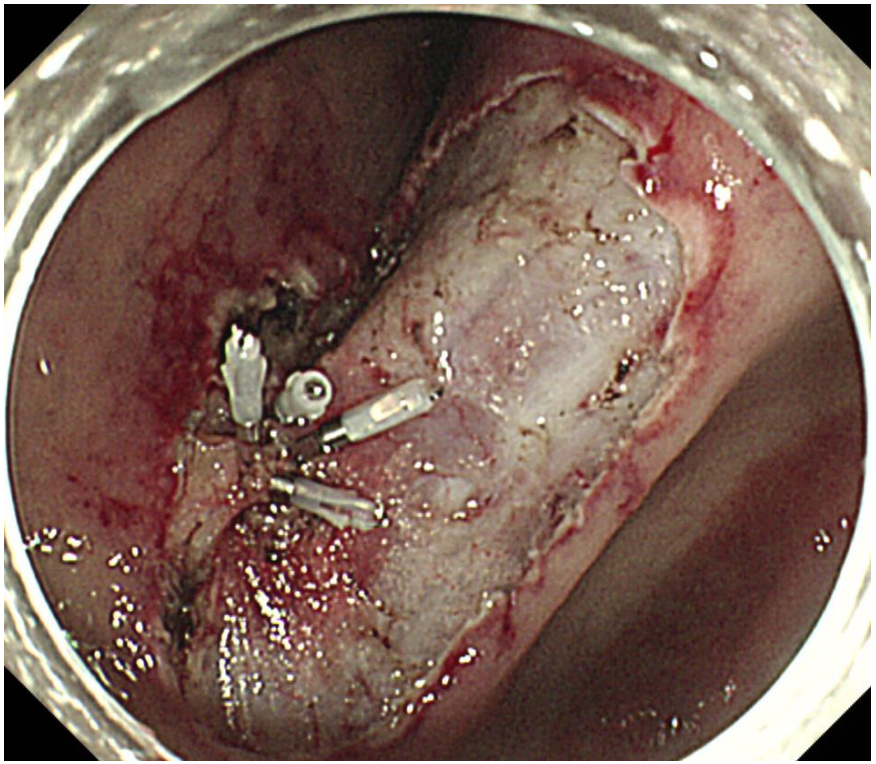

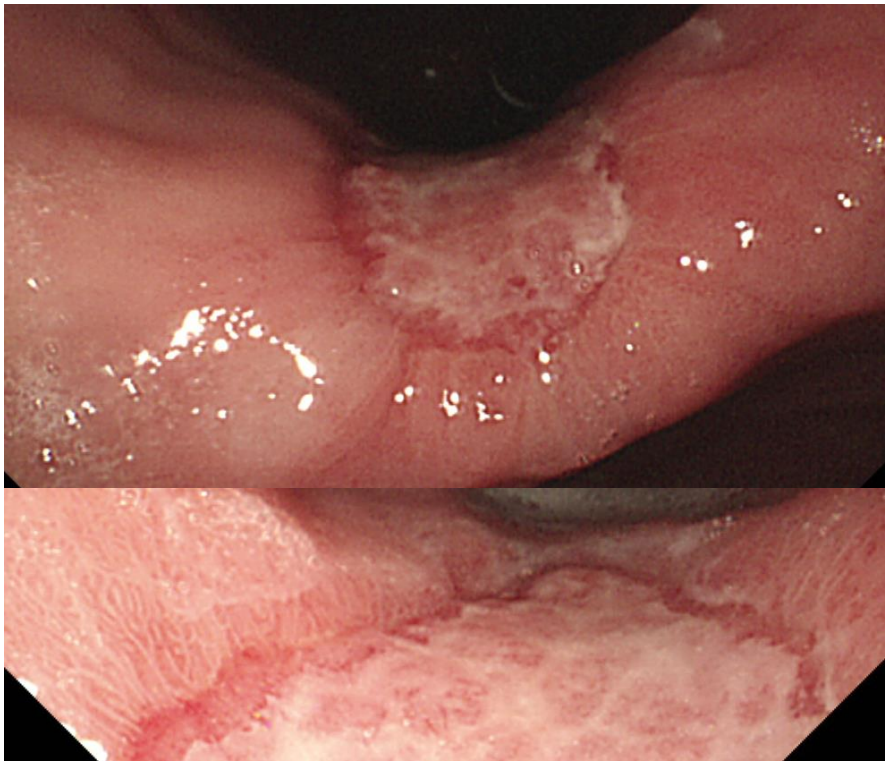

22일 후

Fold가 생기지 않는 경우도 있습니다.

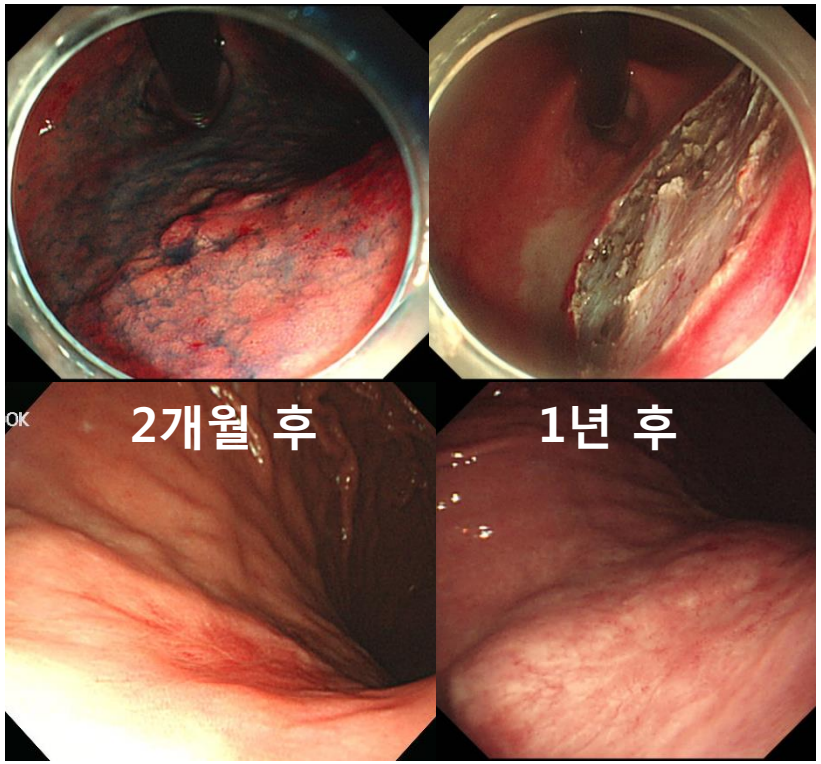

다양한 융기형 반흔 (15%)

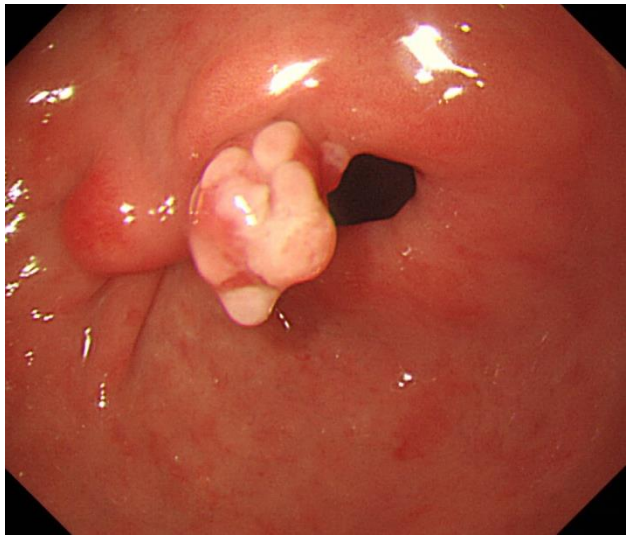
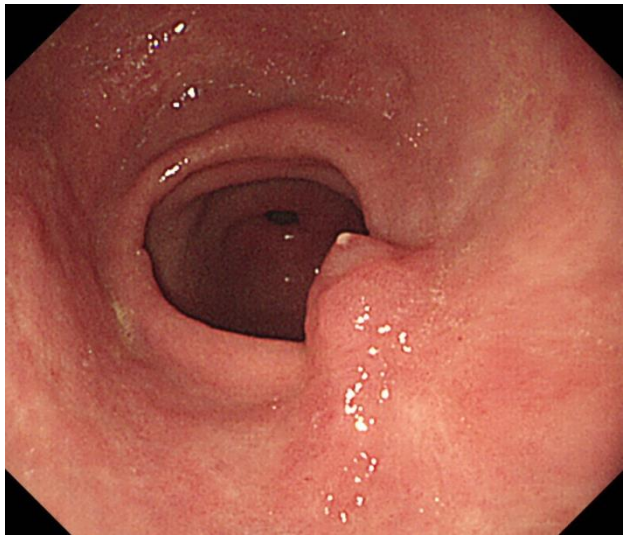
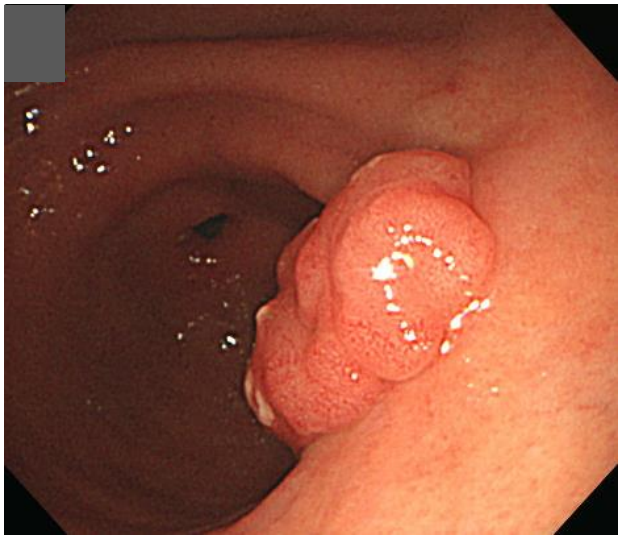

대한위암학회지 2001;1:55-59

배보다 배꼽이 더 큰 경우도 있습니다.

- 작은 위암 ESD 후 큰 융기형 반흔이 수년간 지속

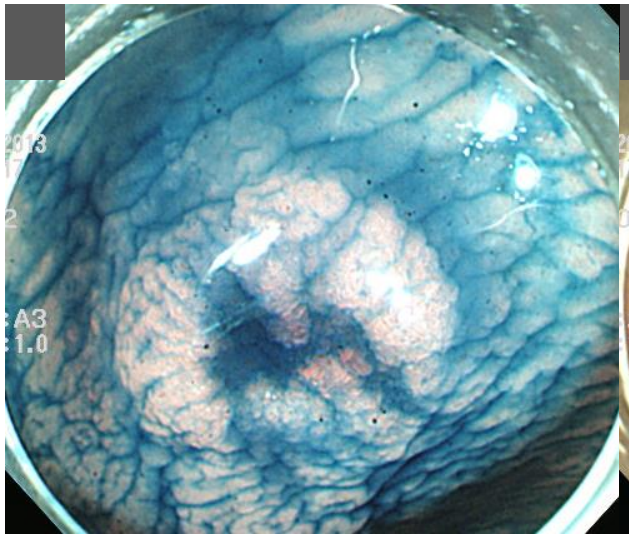

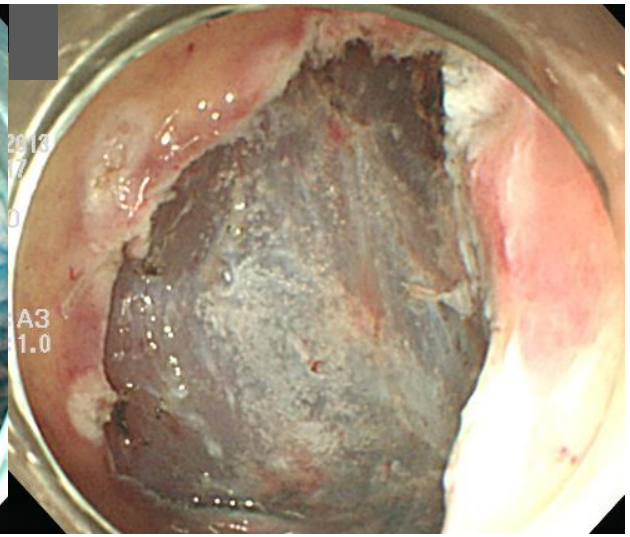

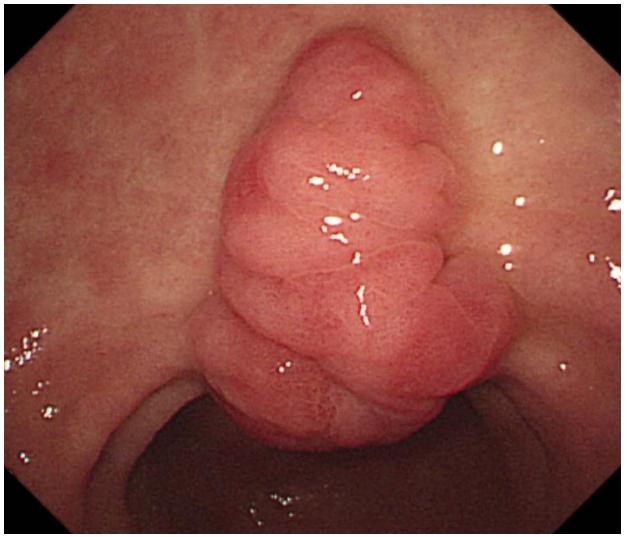

5 years later

8주 후 인공 궤양이 덜 아물기도 합니다.

- M/74, DM, angina, H/O CVA
- M/D, 12mm, MM,

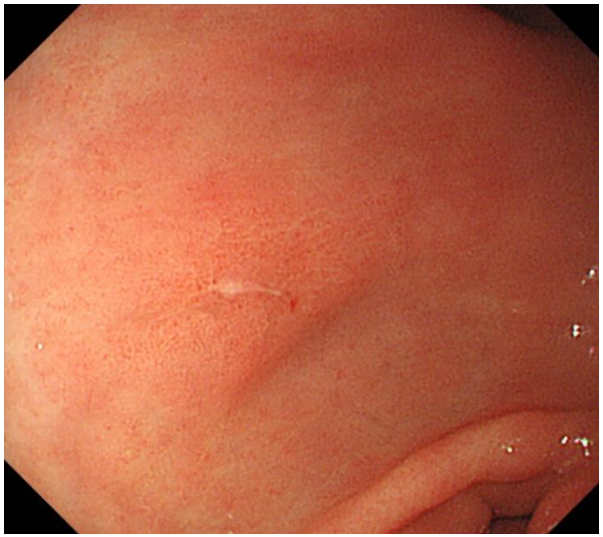

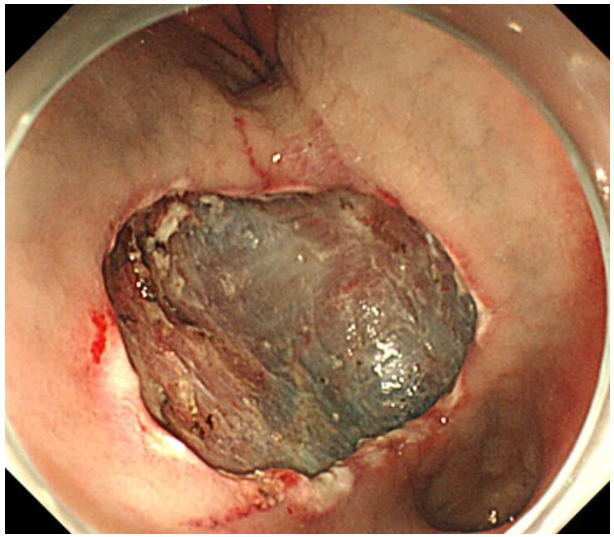

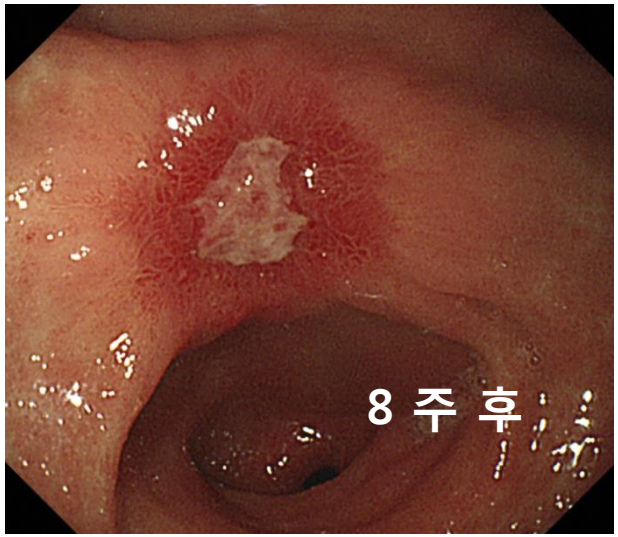

약간 덜 아물었는데 어떻게 하시겠습니까?

- M/D, 34mm, MM, L/V (-/)

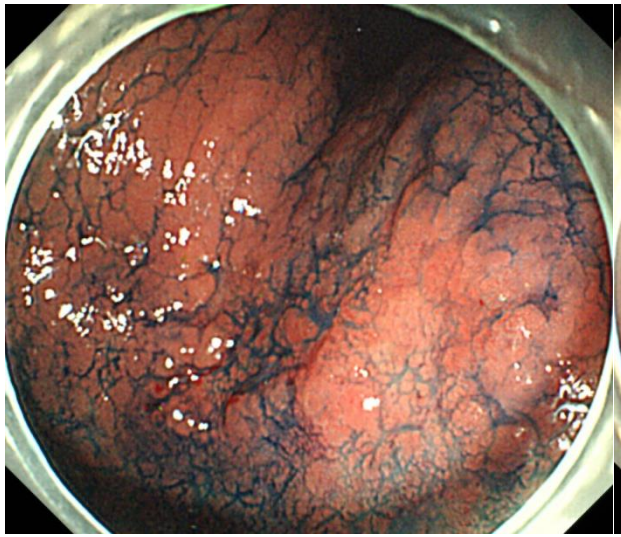

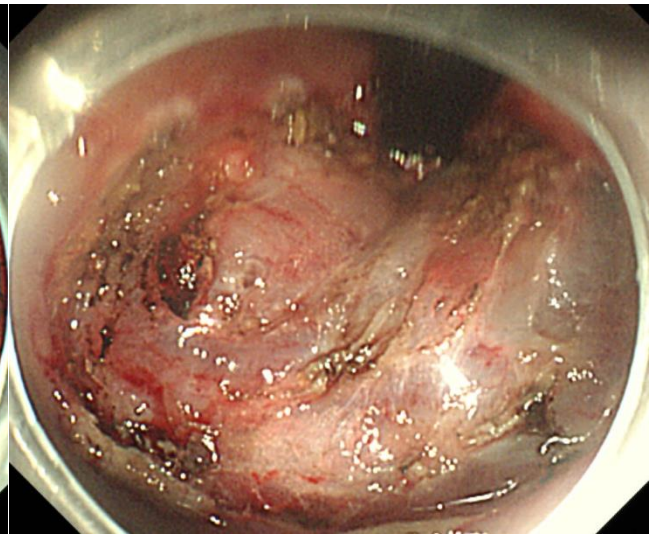

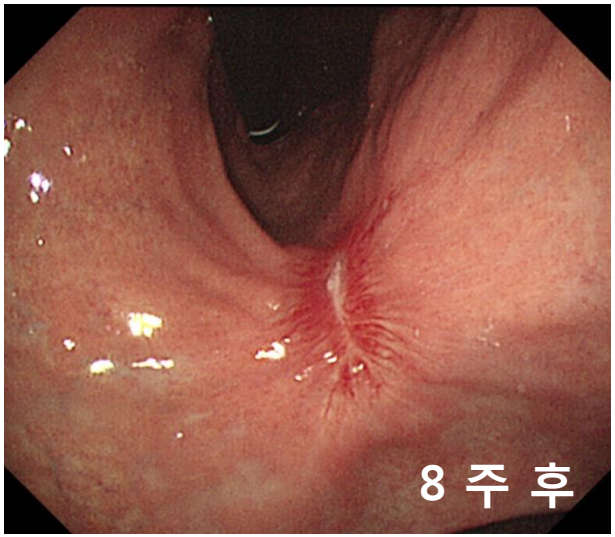

Stricture after a very large ESD

- 14 x 10 cm resection for 7 x 6 cm EGC

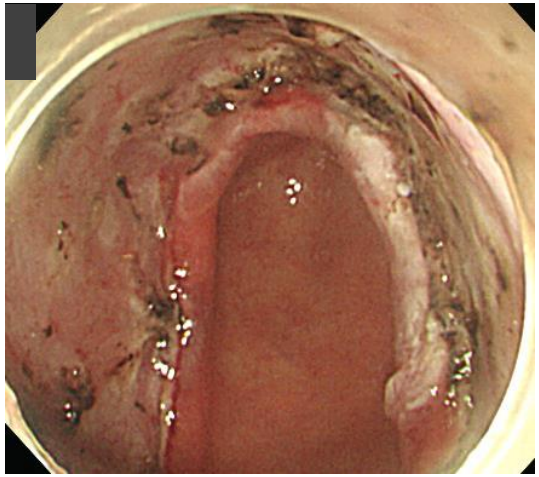

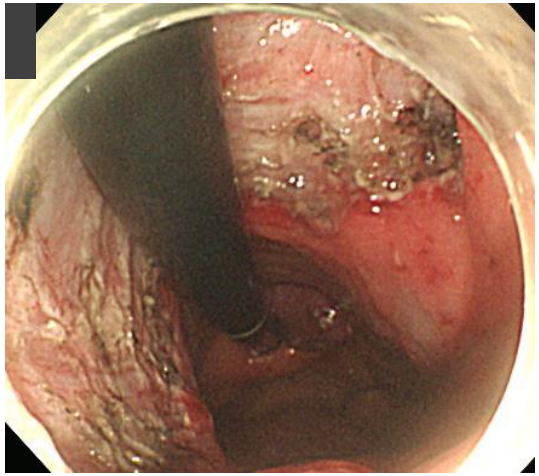

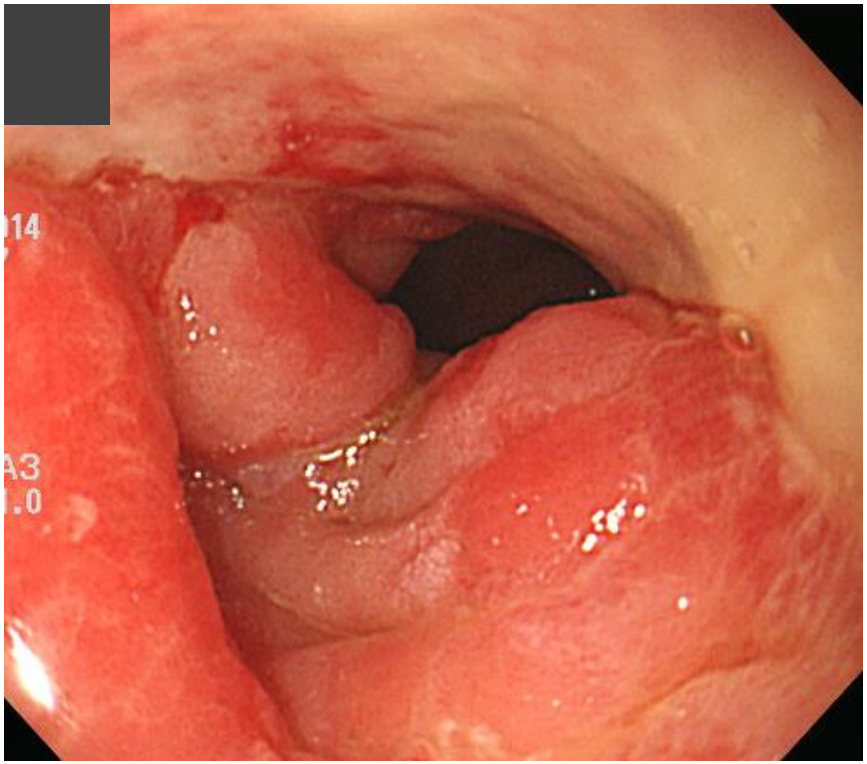

6 weeks after ESD for EGC

세번 ESD 후 상당히 좁아졌으나 증상은 없음

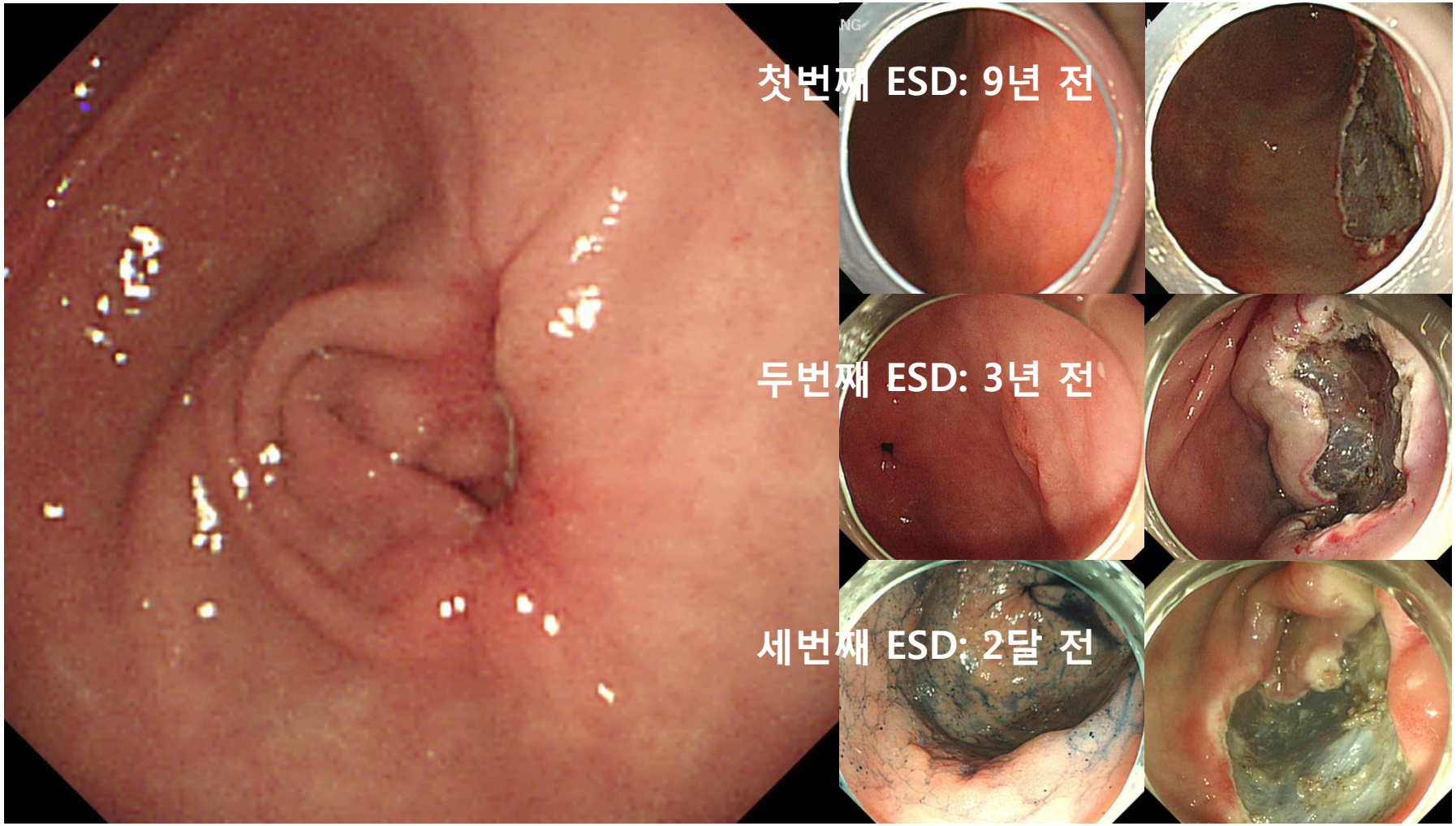

협착 예방을 위한 경구 steroid 치료

8주 코스

- ESD 2일째 Pd 투약 시작
- 1주: 매일 30mg (5mg 6알)
- 2주: 매일 30mg (5mg 6알)
- 3주: 매일 25mg (5mg 5알)
- 4주: 매일 25mg (5mg 5알)
- 5주: 매일 20mg (5mg 4알)
- 6주: 매일 15mg (5mg 3알)
- 7주: 매일 10mg (5mg 2알)
- 8주: 매일 5mg (5mg 1알)
- 9주: 중단

4주 코스

- ESD 2일째 Pd 투약 시작
- 1주: 매일 30mg (5mg 6알)
- 2주: 매일 20mg (5mg 4알)
- 3주: 매일 10mg (5mg 2알)
- 4주: 매일 5mg (5mg 1알)
- 5주: 중단

조직검사 고도선종 → ESD 위암

- 절제 표본: 7.2x4.5cm, LP암: 5.2x1.9cm
- 넓은 ESD였으므로 CP보다 이틀 늦게 퇴원. Steroid 4주 사용

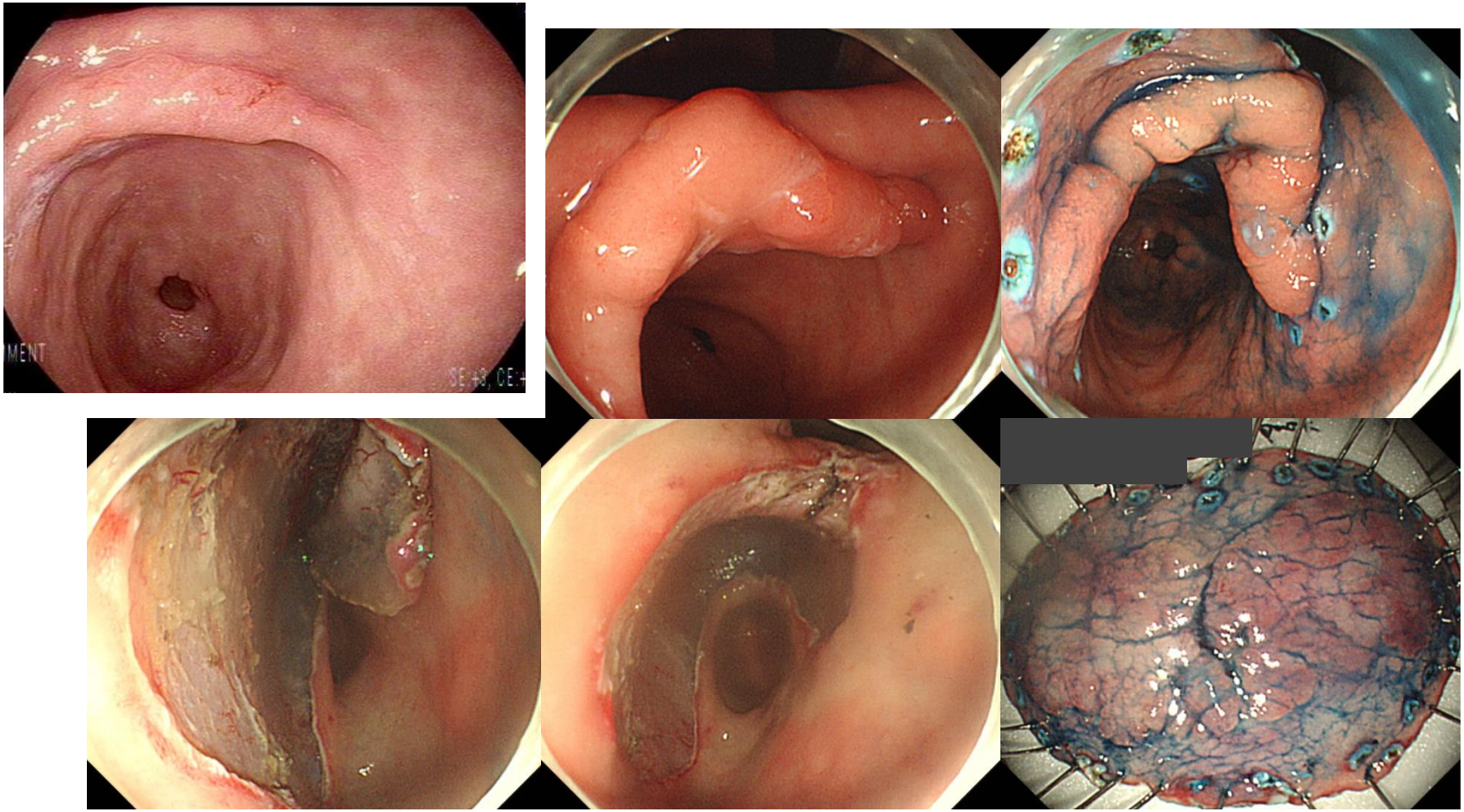

조직검사 고도선종 → ESD 위암

- 절제 표본: 7.2x4.5cm, LP암: 5.2x1.9cm
- 넓은 ESD였으므로 CP보다 이틀 늦게 퇴원. Steroid 4주 사용

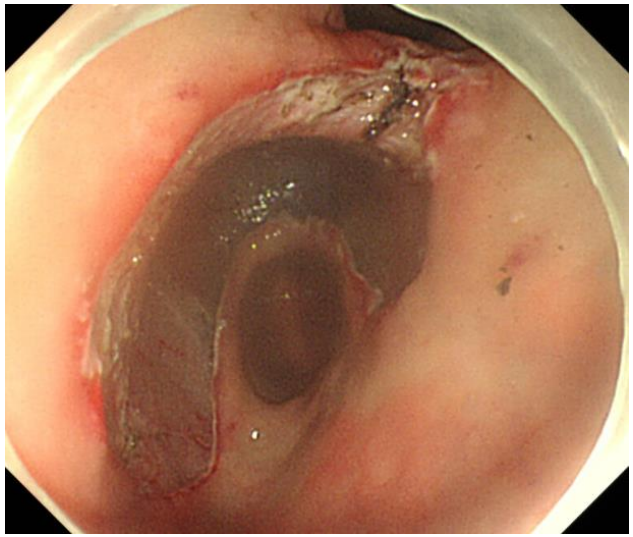

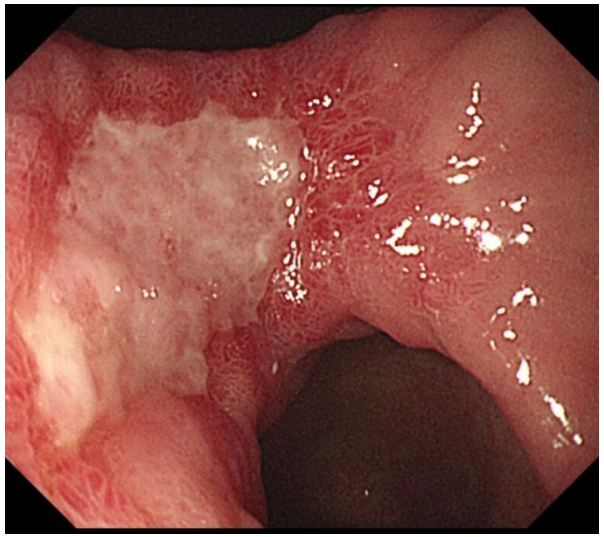

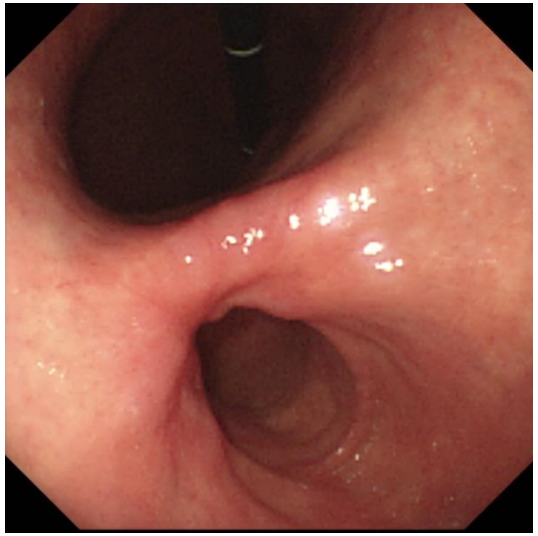

2개월 후

12개월 후

▣ 의견

자세히 관찰한 바 예상보다 병소가 커서 넓은 절제가 되었음. 따라서 협착이나 출혈의 위험이 있음. (1) steroid를 사용해 주시기 바랍니다. ESD 2일째 (2월 22일) Pd 투약 시작하여 "1주 매일 30mg (5mg 6알) --> 다음 1주 매일 20mg (5mg 4알) --> 다음 1주: 매일 10mg (5mg 2알) --> 다음 1주 매일 5mg (5mg 1알) --> 중단"의 스케쥴로 진행하여 주시기 바랍니다. 출혈 위험이 있으므로 CP보다 2일 늦게 (토요일에) 퇴원하도록 아드님께 권했습니다. 가족간 상의하여 답변해 주시겠다고 하셨습니다. 환자측 요구대로 퇴원 일자를 정해주시면 되겠습니다.

ESD 후 병소가 커서 steroid를 PPI와 함께 사용함

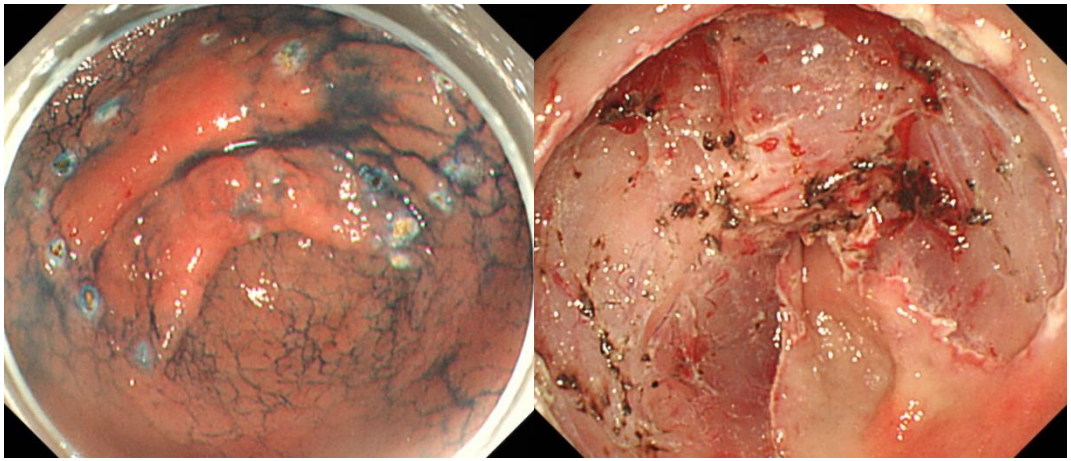

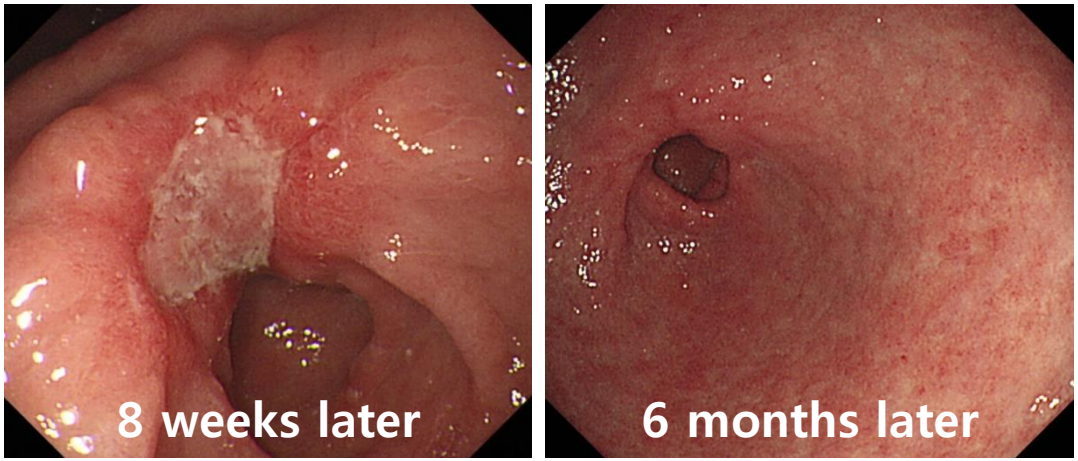

SMC policy – EGD after ESD

- 조기위암/위선종 내시경 치료 후 추적검사

- 조기위암 EMR/ESD: 5년까지 추적 내시경마다 scar에서 조직검사 (1-2점) → 5년 후부터는 재발 의심 소견이 있을 때만 조직검사 (단, 조기위암 EMR/ESD 후 첫 추적 내시경에서는 H. pylori 조직검사도 함께 시행한다.)
- 선종 EMR/ESD: 1년까지 추적 내시경마다 scar에서 조직검사 (1-2점) → 1년 후부터는 재발 의심 소견이 있을 때만 조직검사
- 선종 APC: 재발 의심 소견이 있을 때만 조직검사

1.2cm, M/D, LP암. 7년 후. 조직검사?

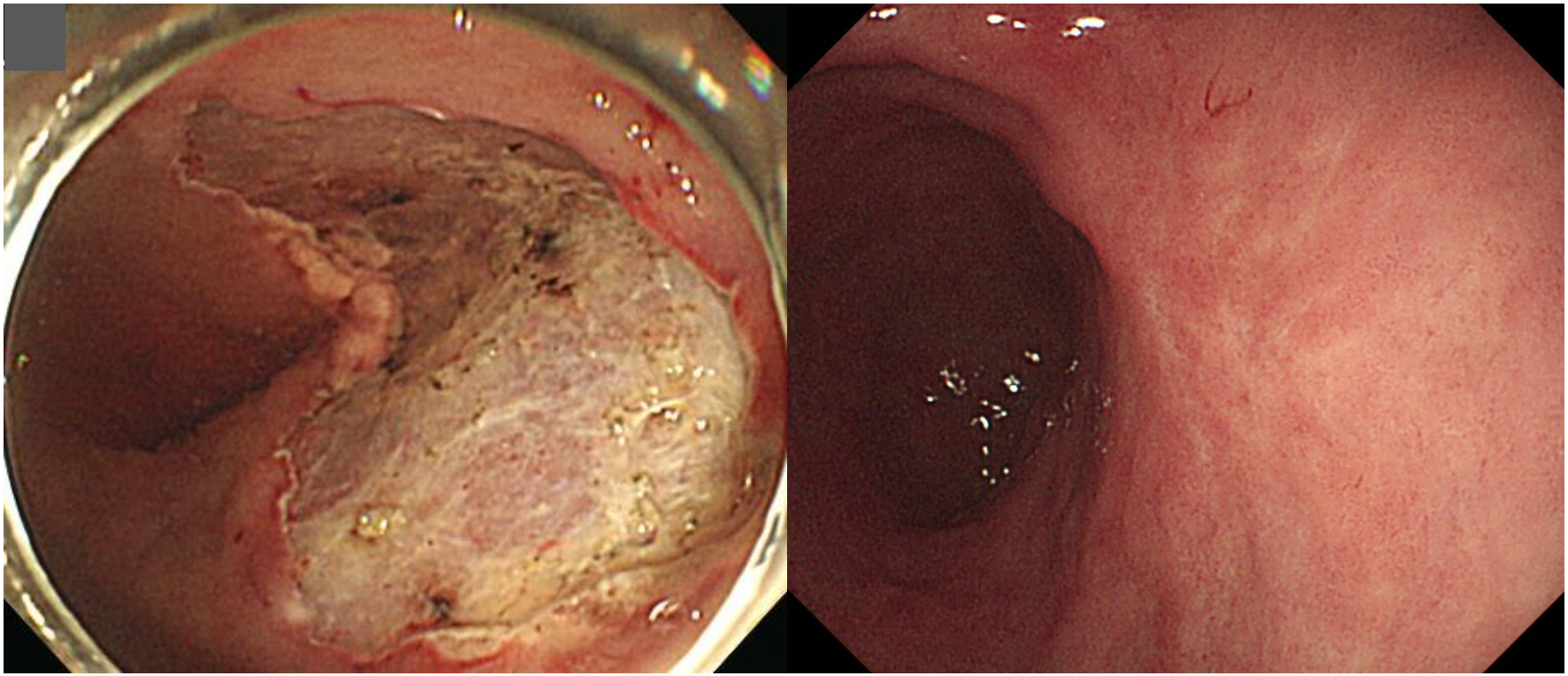

고령이고 NSAID 드시는 분들이 많아서 우연히 위궤양이 발견되기도 합니다.

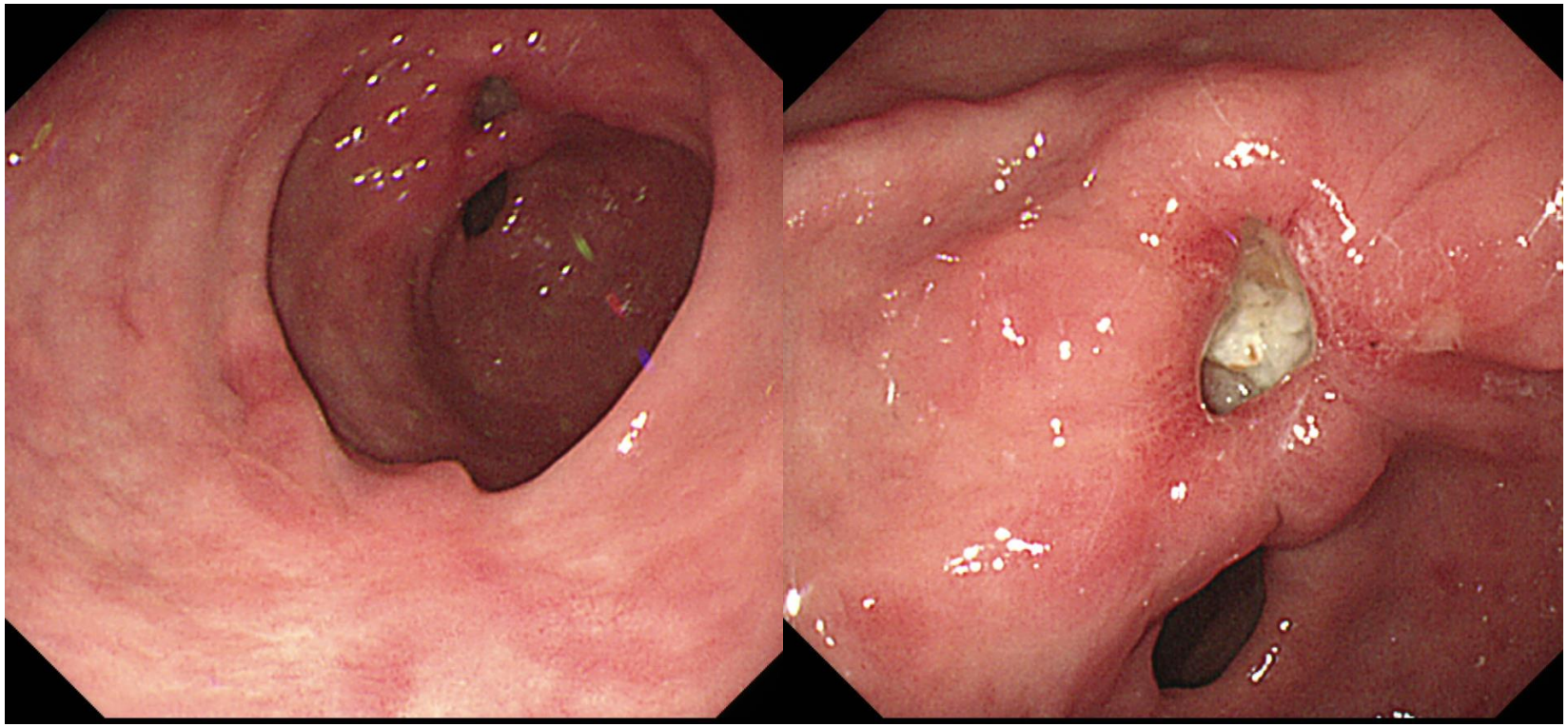

ESD 후 추적 중 우연히 발견된 후두암

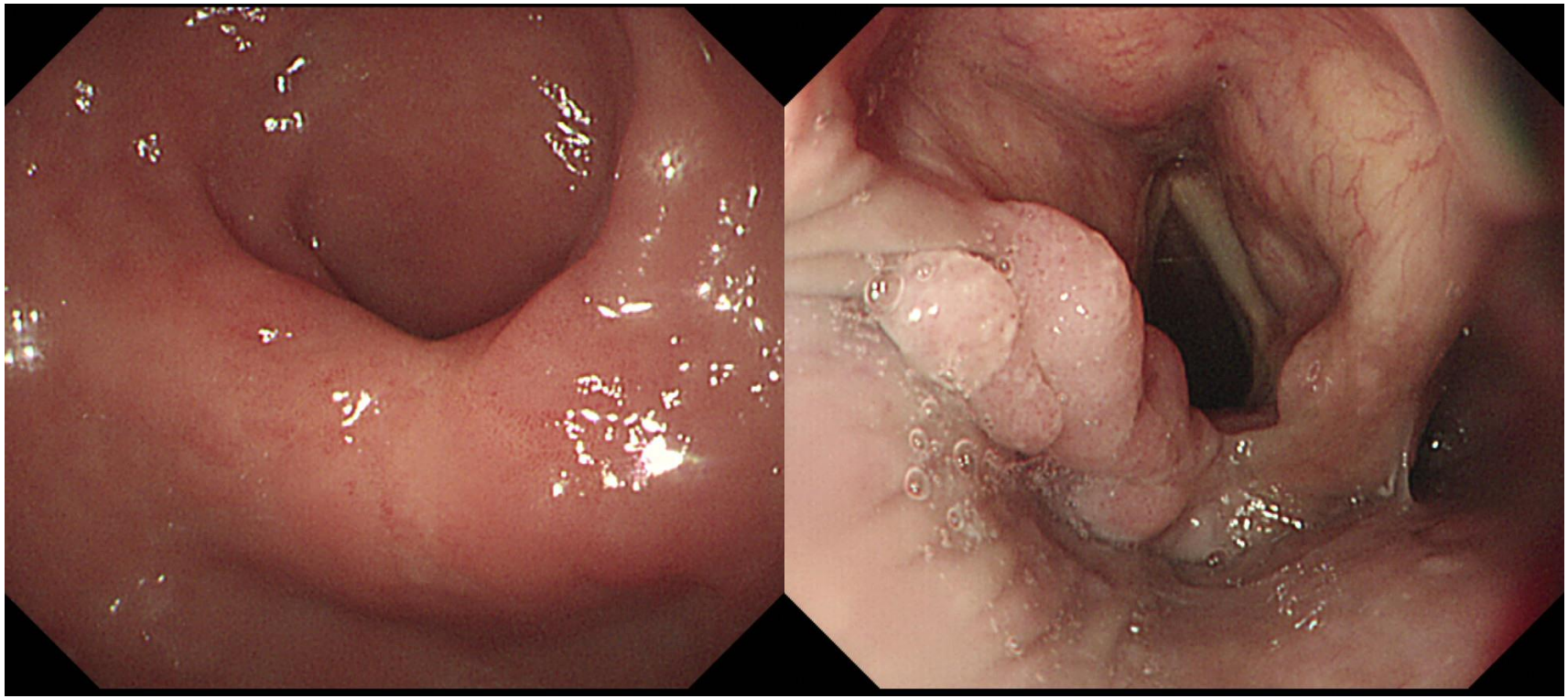

Local recurrence

성균관대학교 의과대학 내과 이준행

2006 국소 재발

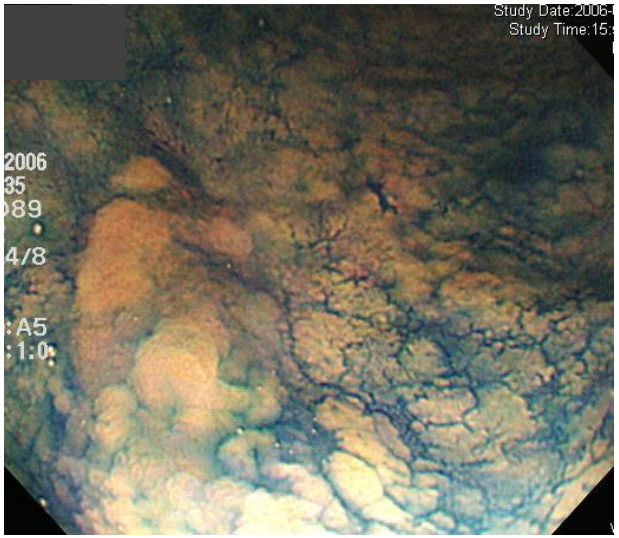

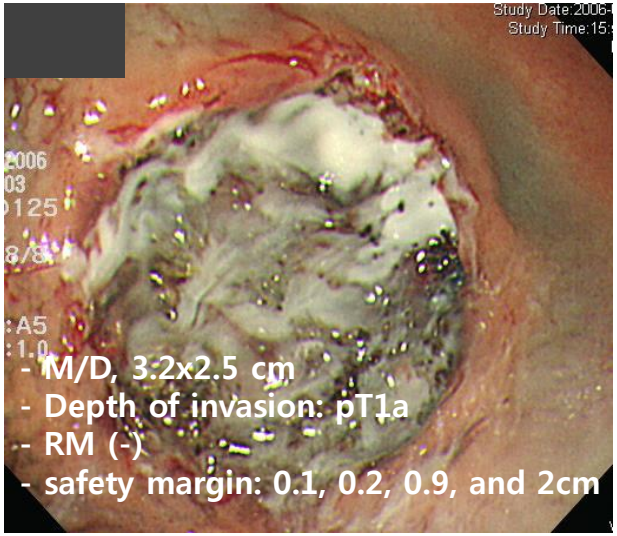

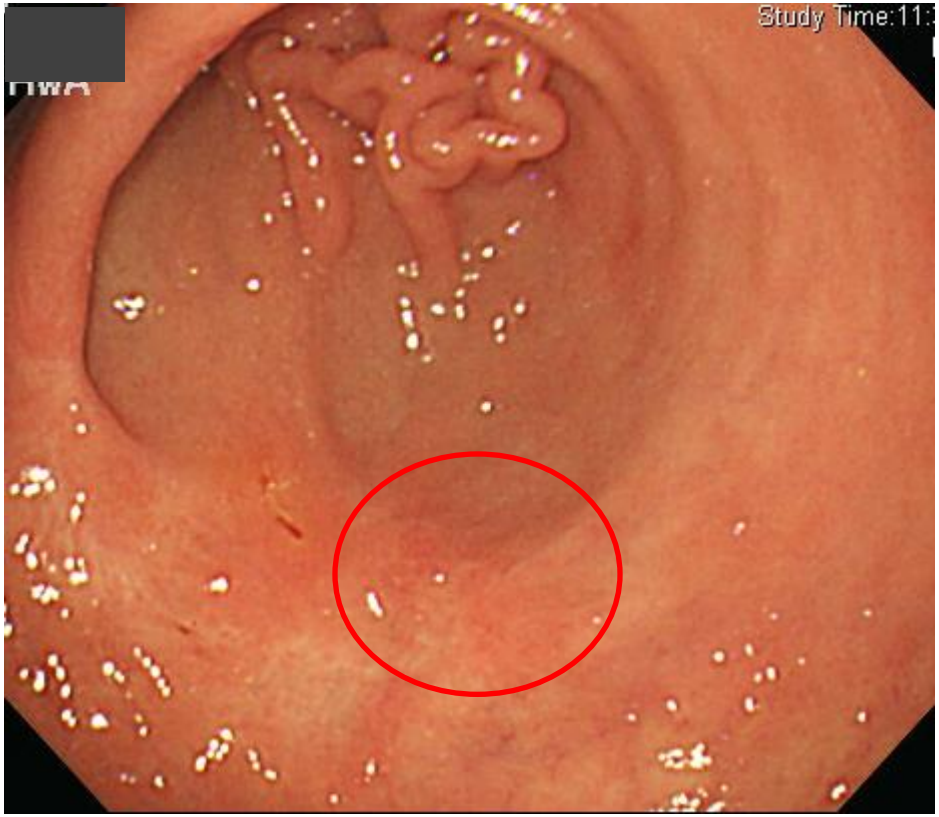

Subtotal gastrectomy: M/D, 0.8x0.4cm, pT1a, RM (-), LN (-)

국소 재발로 의뢰된 환자

- tumor와 scar를 포함하여 en bloc resection 하였음

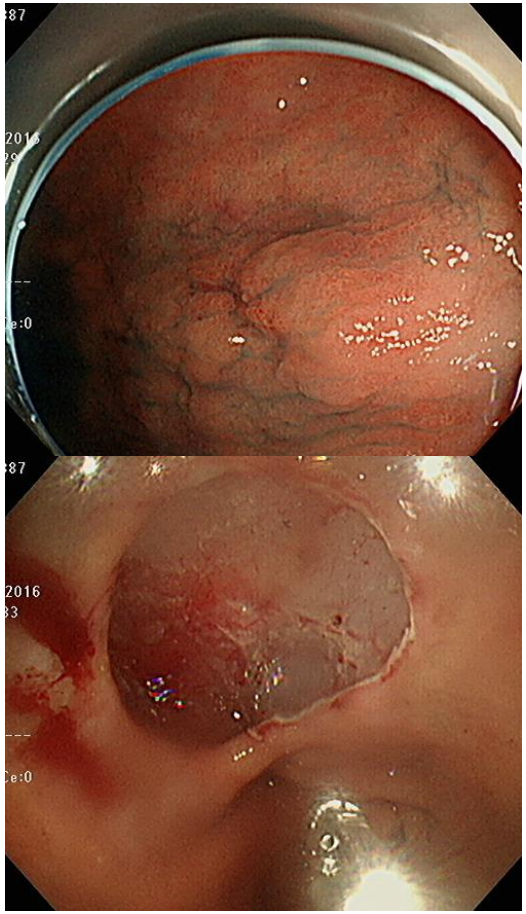

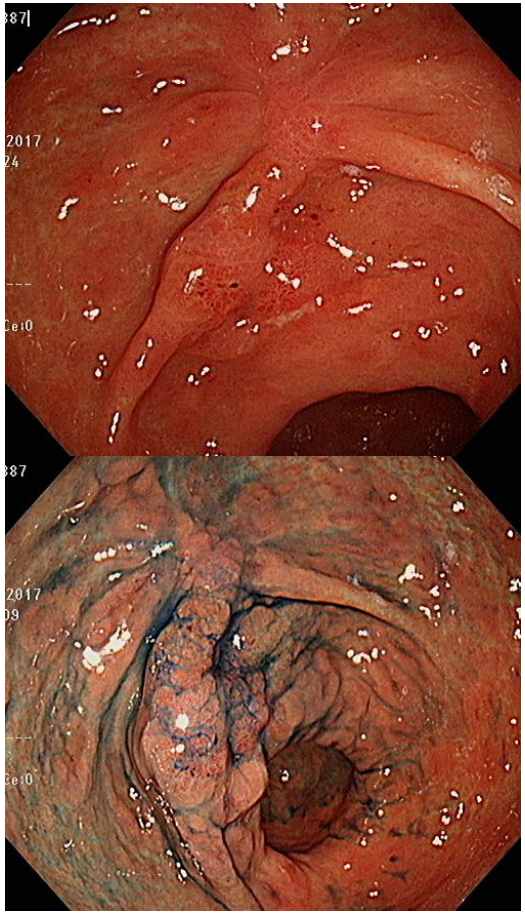

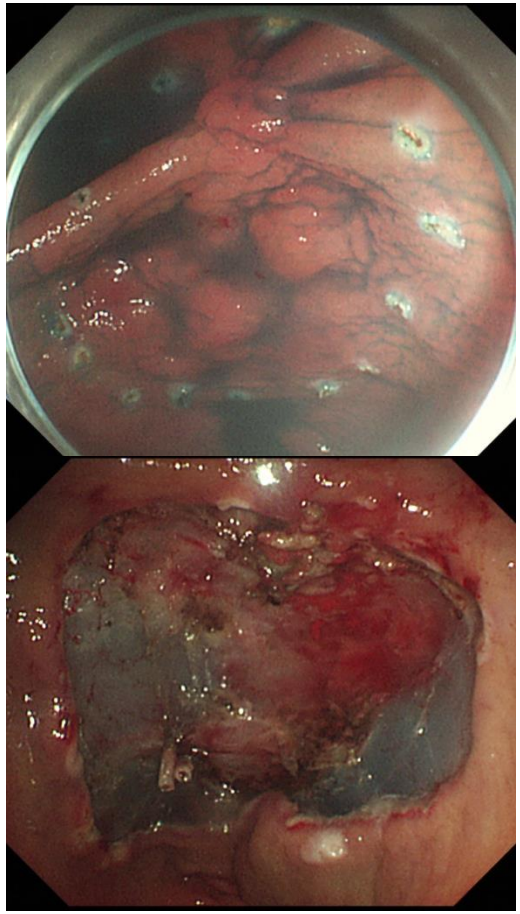

ESD for adenoma with HGD
Review: EGC in MM

EGC at 6 month

Stomach, LC of mid antrum, endoscopic submucosal dissection:

Status post endoscopic submucosal dissection (O17-5219)

Early gastric carcinoma

1. Location : antrum, lesser curvature

2. Gross type : EGC type IIa+IIc

3. Histologic type : tubular adenocarcinoma, well differentiated (foveolar type)

4. Histologic type by Lauren : intestinal

5. Size of carcinoma : (1) longest diameter, **26 mm** (2) vertical diameter, 23 mm

6. Depth of invasion : invades mucosa (**muscularis mucosa**) (pT1a)

7. Resection margin : free from carcinoma(N), safety margin : distal 8 mm, proximal 8 mm, anterior 14 mm, posterior 12 mm

8. Lymphatic invasion : not identified(N)

9. Venous invasion : not identified(N)

10. Perineural invasion : not identified(N)

11. Microscopic ulcer : absent

12. Histologic heterogeneity: absent

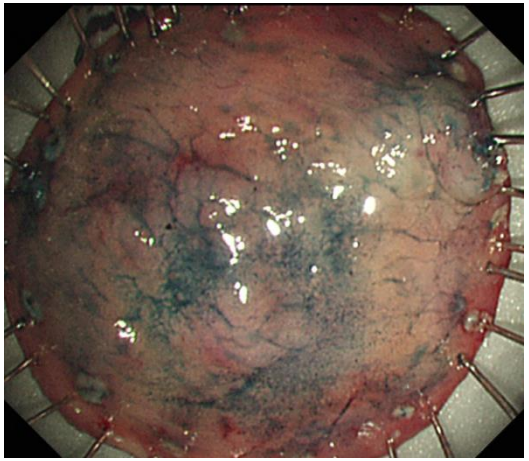

ESD 후 추적관찰을 을 위하여 의뢰된 환자에서 발견된 국소 재발 (3년 3개월)

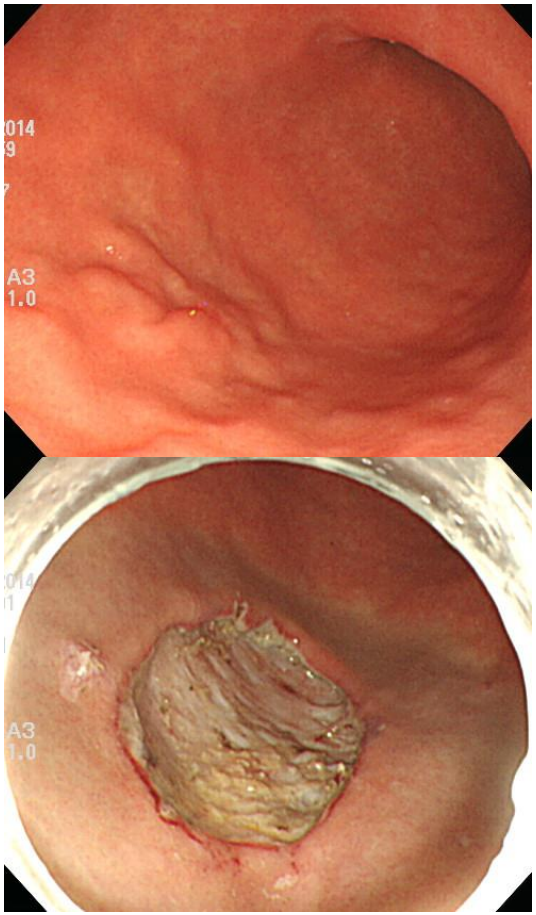

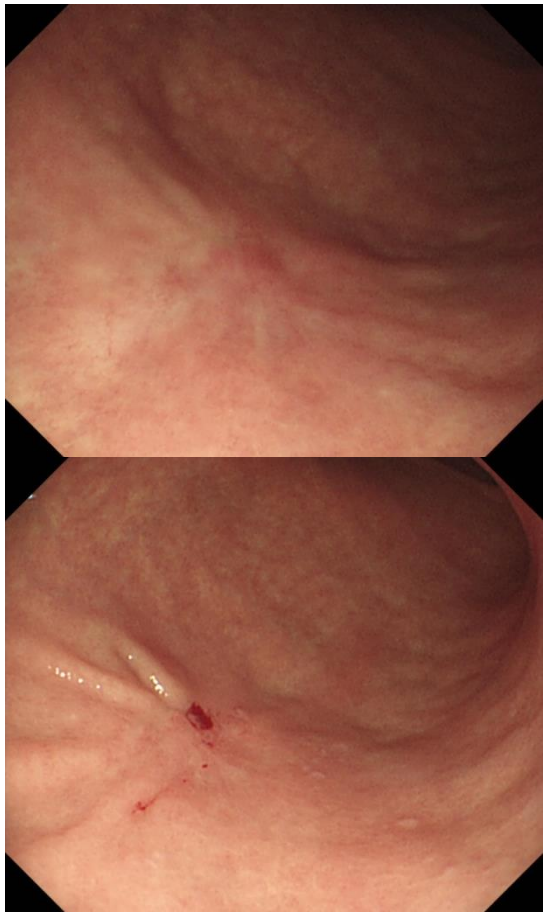

ESD for recurred cancer

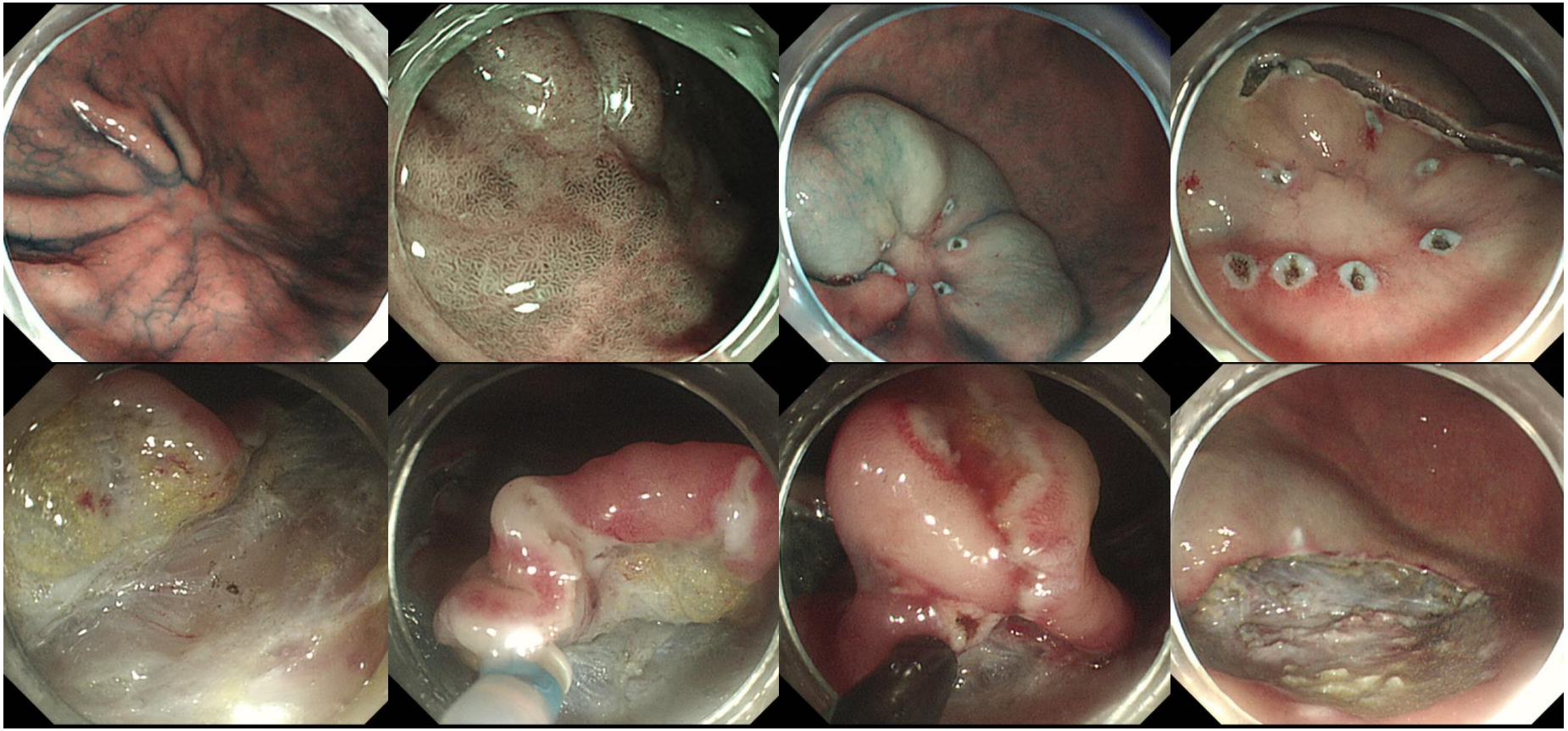

ESD 후 수술 거부 증례

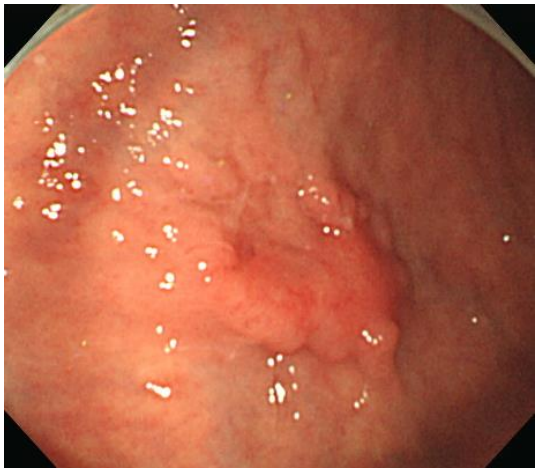

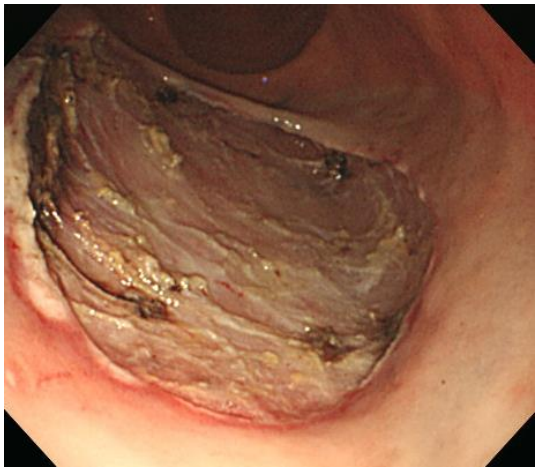

1. Location : antrum, anterior wall
2. Gross type : EGC type IIc
3. Histologic type : tubular adenocarcinoma, M/D >> papillary adenocarcinoma, M/D (about 20%) > tubular adenocarcinoma, P/D (about 10%)
4. Histologic type by Lauren : intestinal
5. Size : 2.8x1.8 cm
6. Depth of invasion : invades submucosa, (depth of sm invasion: **1500 ㎛**) (pT1b)
7. Resection margin: free from carcinoma
8. **Lymphatic invasion : present**
9. Venous invasion : present
10. Perineural invasion : not identified
11. Microscopic ulcer : absent
12. Histologic heterogeneity: present

ESD 후 수술 거부 → 38개월 후 재발

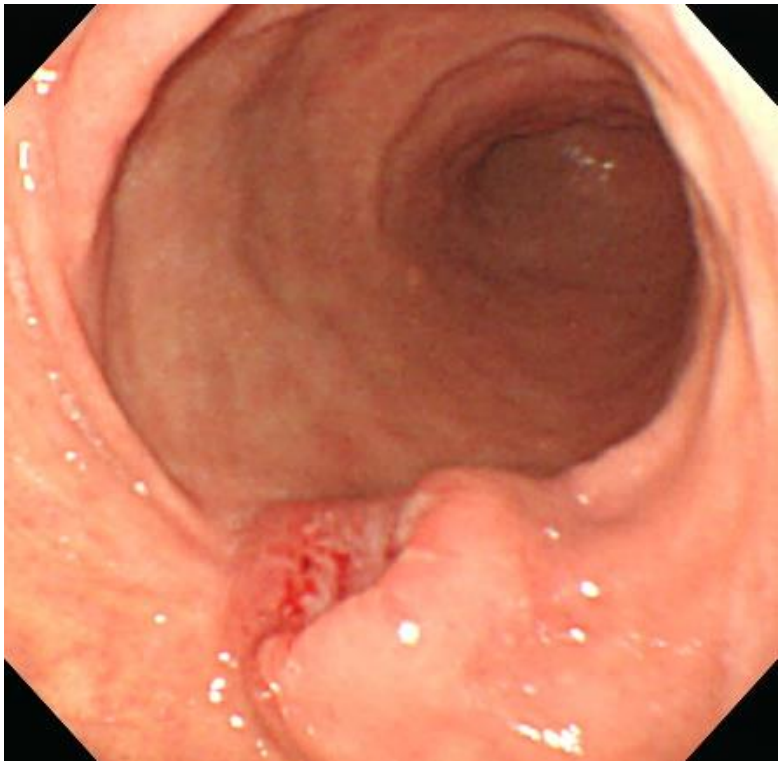

Recurrent mass at 38 months

Advanced gastric carcinoma

Histologic type : tubular adenoca (M/D)

Size : 2.8x2.4 cm

Penetrates subserosal connective tissue

Lymph node metastasis : positive (1/34)

Lymphatic invasion : present

Venous invasion : not identified

Perineural invasion : not identified

Peritoneal cytology : negative

Limited role of follow-up EGD

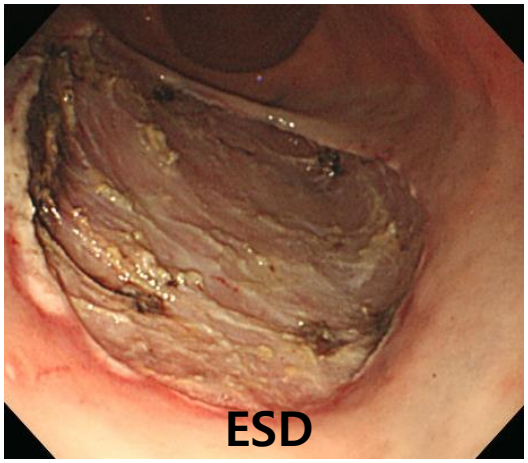

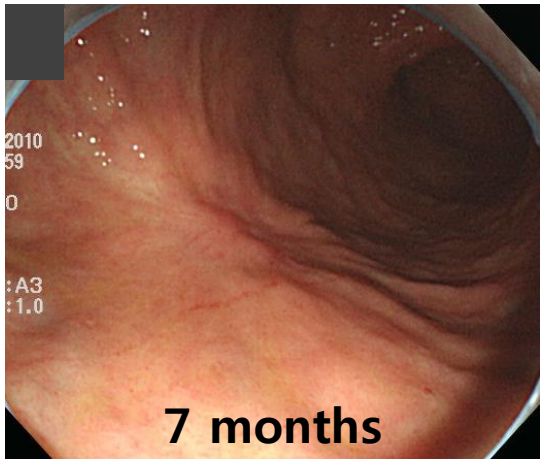

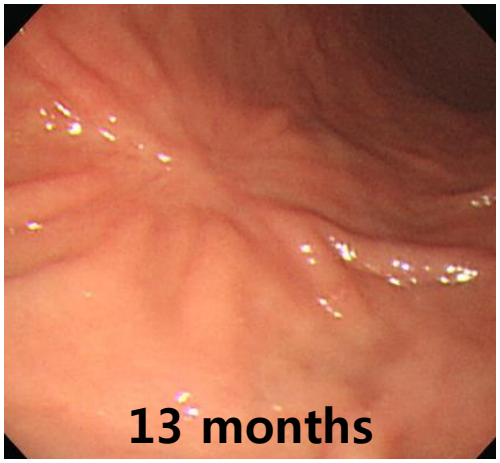

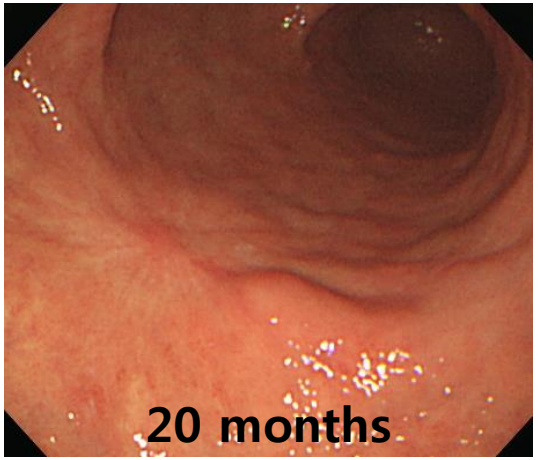

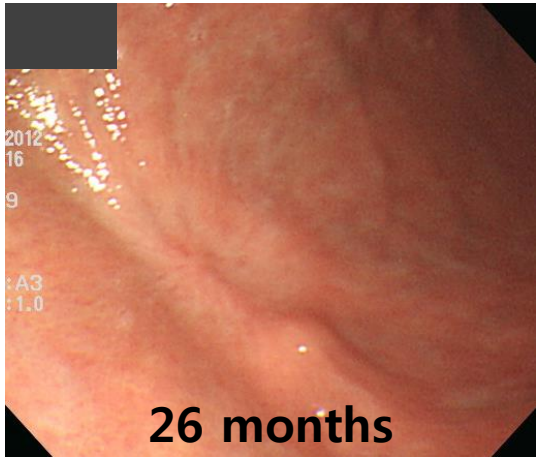

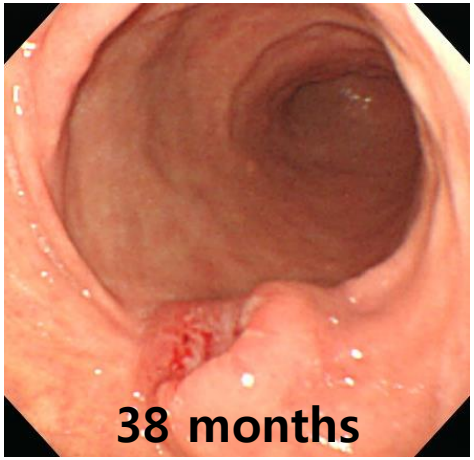

어떤 경우에 local recur를 의심?

- Unclear tumor border before ESD
- Not sufficient resection margin
- Larger tumor
- SM invasion
- Mixed histology / undifferentiated type
- Delayed healing
- Asymmetry, focal hyperemia, SMT-like buldging

Box summary

- 조기위암 내시경 절제술 후 extragastric recurrence는 발생한다. 대형 cohort에서 내시경적 완전절제 후 extragastric recurrence의 비율은 0.15-0.5%이다.
- 조기위암 내시경 절제술 후 follow up loss가 많다는 점을 고려해야 한다.
- 국소 재발은 다양한 모습을 보일 수 있다.